


# Mitral Valve Disease

Eddie Distler PGY-7

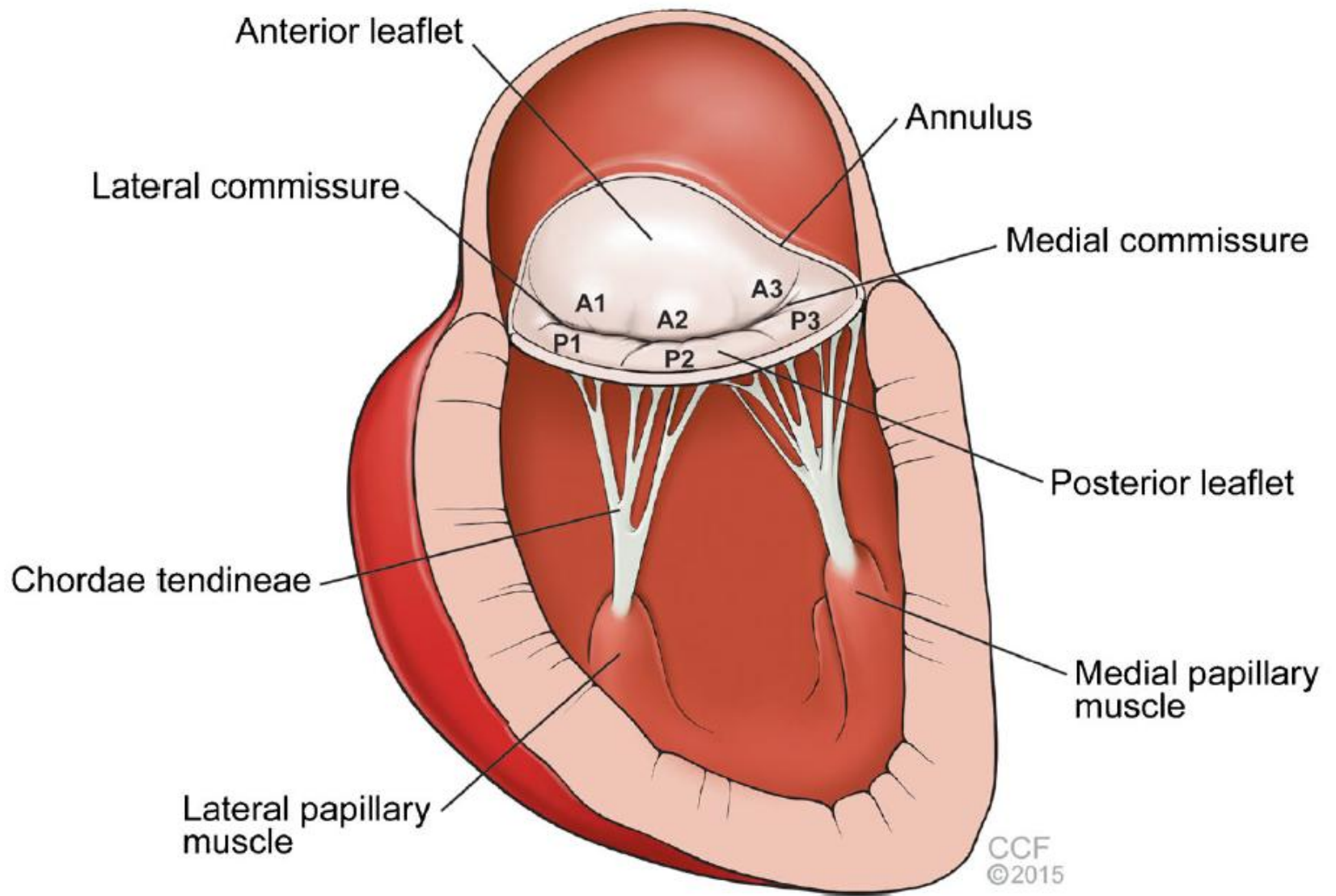
Interventional Cardiology Fellow

University of Arizona College of  
Medicine Phoenix

# Objectives



1. Define the anatomy of the mitral valve and terms of mitral valve disorders
2. Define severe MS. List common causes. When to interval echo?
3. When is exercise echocardiography stress testing helpful in MS?
4. Who should get intervention for MS?
5. What is the definition of severe MR and interval echo?
6. Which features suggest that surgical repair will be effective?
7. Describe the management of acute MR.
8. Describe the indication for MV repair with clip vs replacement for chronic MR.




# MV Stenosis - Etiology

- **Rheumatic heart disease (RHD)** most common cause in world, especially in developing countries.
  - Related to immune response by cross-reactivity between streptococcal antigen and valve tissue.
  - Although any cardiac valve may be involved, the mitral valve is almost always affected.
  - Commissural fusion – “**Fish-mouth**” appearance of the MV orifice
  - Leaflet thickening, especially at the free edges – Shortening and fusion of the chordae
    - **hockey-stick** appearance of the leaflet, particularly the anterior, on echocardiography.

# MV Stenosis - Etiology

- **Radiation valvulitis:** which typically manifests 10 to 20 years after mediastinal radiation therapy
- **Congenital causes:** very rare, such as cor triatriatum, parachute mitral valve, double-orifice mitral valve, or supralvalvular mitral ring
- **Systemic inflammatory disorders** such as lupus erythematosus and RA may occasionally lead to valvulitis and resulting MS.
- **Obstructing lesions** such as a large atrial myxoma or infected vegetation which may cause functional MS.
- **Mitral annular calcification (MAC):** common in elderly and w/ advanced renal disease, rare cause of mitral stenosis.


# MV Stenosis - Quantification



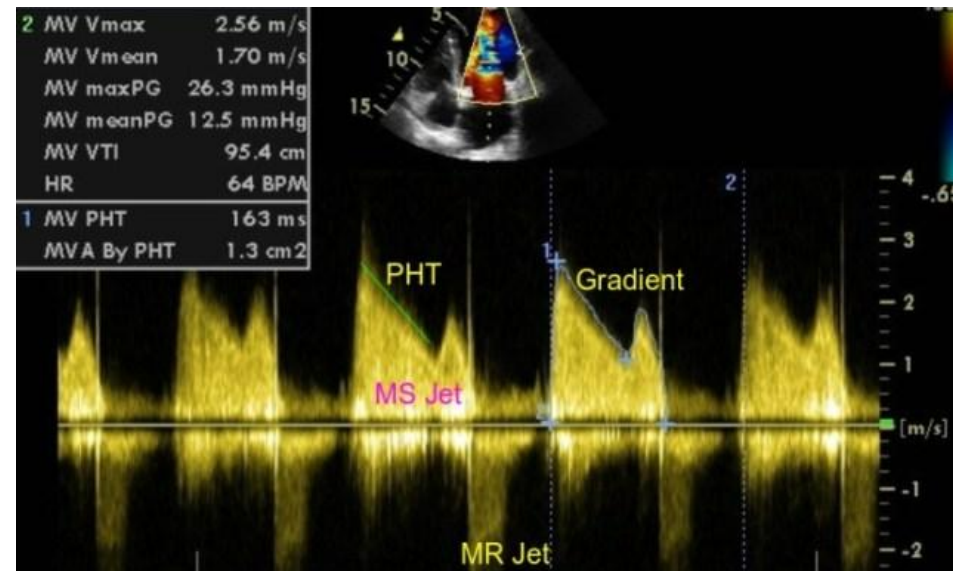
1. Mean diastolic trans-mitral pressure gradient
2. MV area
3. Secondary changes including LA enlargement and right sided increased chamber size and pressure

# Severe MV stenosis by gradient

2nd year



- Mean gradient  $>10$  mmHg  $\rightarrow$  Severe MS
- 5–10 mmHg  $\rightarrow$  Moderate MS
- $<5$  mmHg  $\rightarrow$  Mild MS



# MVA - Severity

Severe if it is  $\leq 1.5$  cm<sup>2</sup>





# Secondary changes of MS

- At area less than  $2\text{cm}^2$ , a diastolic pressure gradient develops between the LA and LV → increased LA pressures and decreased forward flow
- Tachycardia is BAD! in MS
  - shortens the diastolic filling time, leading to an increase in the the transmitral gradient.
- Consequences of increased LA pressures:
  - LA enlargement with increased risk of atrial arrhythmias, particularly atrial fibrillation, and systemic thromboembolism (valvular a fib...)
  - Increased pulmonary pressures with resultant pulmonary edema and pulmonary hypertension → RV failure
- Consequences of decreased forward flow:
  - Low cardiac output: due to poor LV filling.

# When should stress testing be ordered for MS assessment?

Third Year



# MV stenosis stress testing (stress echocardiogram)

Discrepancy between the reported symptoms and the severity of MS.

- “Asymptomatic” with severe MS → exercise testing can help confirm if the patient is able to achieve an adequate workload without the development of symptoms.
- Moderate MS and “severe” symptoms → stress testing can unmask hemodynamically significant MS during exercise.
- Typically, in addition to recording symptoms, MV gradients and estimated right-sided pressures should be measured during the stress test and these results included in the decision-making regarding intervention.

# Medical Management of MS

- Decrease pulmonary congestion with diuretics
- **Control HR**, primarily with beta-blockers, for symptomatic relief and to **decrease gradient via increasing filling time**
- Anticoagulation with **warfarin** is recommended in cases of atrial fibrillation.
- Novel oral anticoagulants should **NOT** be used in cases of MS

# Rheumatic Mitral Stenosis

Severe MS  
MVA  $\leq 1.5 \text{ cm}^2$

Progressive MS  
MVA  $> 1.5 \text{ cm}^2$

Symptomatic  
Stage D

Asymptomatic  
stage C

Exertional  
symptoms

Pliable valve  
No clot  
<2+ MR

NO

Severe  
symptoms  
NYHA III-IV

Pliable valve  
No clot  
<2+ MR

Stress test  
Hemodynamically  
significant MS

YES

Surgical  
candidate

PASP  
>50 mm Hg

New AF

Pliable valve  
No clot  
<2+ MR

YES

NO

PMBC at CVC  
(1)

MV surgery\*  
(1)

PMBC at  
CVC  
(2b)

PMBC at  
CVC  
(2a)

PMBC at CVC  
(2b)

## Recommendation for Nonrheumatic Calcific MS

COR	LOE	Recommendation
<b>2b</b>	<b>C-LD</b>	1. In severely symptomatic patients (NYHA class III or IV) with severe MS (mitral valve area $\leq 1.5$ cm <sup>2</sup> , Stage D) attributable to extensive mitral annular calcification, valve intervention may be considered only after discussion of the high procedural risk and the individual patient's preferences and values. <sup>1-3</sup>

# Intervention should be performed on all of the following except?

2<sup>nd</sup> year


- A. Asymptomatic patients with severe MS who have new onset of AF
- B. Symptomatic patients with moderate MS if there is evidence of hemodynamically significant MS during exercise
- C. Preoperatively, in asymptomatic severe MS undergoing elective moderate- or high-risk non-cardiac surgery.
- D. Asymptomatic patients with severe MS
- E. Preconception, in symptomatic women with moderate or severe MS (mitral valve area  $\leq 1.5$  cm<sup>2</sup>).

# Intervention should be performed on all of the following except?

- A. Asymptomatic patients with severe MS who have new onset of AF
- B. Symptomatic patients with moderate MS if there is evidence of hemodynamically significant MS during exercise
- C. Preoperatively, in asymptomatic severe MS undergoing elective moderate- or high-risk non-cardiac surgery.
- D. Asymptomatic patients with severe MS**
- E. Preconception, in symptomatic women with moderate or severe MS (mitral valve area  $\leq 1.5$  cm<sup>2</sup>).



# Indications for MV stenosis intervention



1. Asymptomatic patients with severe MS who have new onset of AF (Class IIB recommendation).
2. Symptomatic patients with moderate MS if there is evidence of hemodynamically significant MS during exercise (Class IIB recommendation).
3. Preoperatively, in asymptomatic severe MS undergoing elective moderate- or high-risk non-cardiac surgery.
4. Symptomatic patients with severe MS (Class I recommendation).
5. Preconception, in symptomatic women with moderate or severe MS (mitral valve area  $\leq 1.5$  cm<sup>2</sup>).

# QUESTION

First year

A 33-year-old man is evaluated for a 5-month history of exercise intolerance and shortness of breath when walking up stairs. No past medical history.

On physical examination, BP: 140/70 mm Hg, HR: 62/min, and RR 16/min. Irregularly irregular rhythm. An opening snap is heard after S2, followed by a grade 1/6 diastolic rumble at the apex.

EKG shows A Fib. TTE findings are consistent with rheumatic valve disease, showing a mildly thickened mitral valve with minimal calcification and mild restriction in leaflet motion. The subchordal apparatus is mildly thickened, and there is mild mitral regurgitation and marked left atrial enlargement. Mean gradient across the mitral valve is 13 mm Hg. Mitral valve area is 1.2 cm<sup>2</sup>. TEE shows no left atrial appendage thrombus and confirms TTE findings.

In addition to AC, which of the following is the most appropriate management?

- A. Medical management; repeat echocardiogram in 6 months
- B. Mitral valve replacement
- C. Percutaneous mitral balloon valvuloplasty
- D. Surgical mitral valve repair

# QUESTION

First year

A 33-year-old man is evaluated for a 5-month history **of exercise intolerance and shortness of breath** when walking up stairs. No past medical history.

On physical examination, BP: 140/70 mm Hg, HR: 62/min, and RR 16/min.. Irregularly irregular rhythm. An opening snap is heard after S2, followed by a grade 1/6 diastolic rumble at the apex.

EKG shows **A Fib**. TTE findings are consistent with rheumatic valve disease, showing a mildly thickened mitral valve **with minimal calcification** and mild restriction in leaflet motion. The subchordal apparatus is mildly thickened, and there **is mild mitral regurgitation** and marked left atrial enlargement. Mean gradient across the mitral valve is 13 mm Hg. Mitral valve area is 1.2 cm<sup>2</sup>. TEE shows no left atrial appendage thrombus and confirms TTE findings.

In addition to AC, which of the following is the most appropriate management?

- A. Medical management; repeat echocardiogram in 6 months
- B. Mitral valve replacement
- C. Percutaneous mitral balloon valvuloplasty
- D. Surgical mitral valve repair

# QUESTION

A 33-year-old man is evaluated for a 5-month history of exercise intolerance and shortness of breath when walking up stairs. No past medical history.

On physical examination, BP: 140/70 mm Hg, HR: 62/min, and RR 16/min.. Irregularly irregular rhythm. An opening snap is heard after S2, followed by a grade 1/6 diastolic rumble at the apex.

EKG shows A Fib. TTE findings are consistent with rheumatic valve disease, showing a mildly thickened mitral valve with minimal calcification and mild restriction in leaflet motion. The subchordal apparatus is mildly thickened, and there is mild mitral regurgitation and marked left atrial enlargement. Mean gradient across the mitral valve is 13 mm Hg. Mitral valve area is 1.2 cm<sup>2</sup>. TEE shows no left atrial appendage thrombus and confirms TTE findings.

In addition to AC, which of the following is the most appropriate management?

- A. Medical management; repeat echocardiogram in 6 months
- B. Mitral valve replacement
- C. Percutaneous mitral balloon valvuloplasty**
- D. Surgical mitral valve repair

# QUESTION

A 45-year-old F is evaluated for a 12 mo history of exertional dyspnea. She experiences shortness of breath during mild exertion, such as house chores and walking on flat surfaces. She describes her symptoms as debilitating, as they have interfered with her activities of daily living. She has not had symptoms at rest, and she has had no palpitations. She takes hydrochlorothiazide for hypertension.

On physical examination, vitals are normal.. There is an early diastolic sound followed by a soft rumble heard best at the apex. S2 is normal.

An echocardiogram shows findings consistent with moderate rheumatic mitral stenosis and minimal mitral regurgitation. The mean gradient across the mitral valve is 8 mm Hg, and the mitral valve area is calculated to be 1.8 cm<sup>2</sup>. The mitral valve is pliable. Moderate pulmonary hypertension is present, with an estimated pulmonary artery systolic pressure of 45 mm Hg.

Which of the following is the most appropriate next step in management?

- A Exercise echocardiography
- B Medical therapy
- C Percutaneous balloon mitral valvuloplasty
- D Surgical mitral valve replacement

# QUESTION

A 45-year-old F is evaluated for a 12 mo history of **exertional dyspnea**. She experiences shortness of breath during **mild exertion**, such as house chores and walking on flat surfaces. She describes her symptoms as debilitating, as they have interfered with her activities of daily living. She has not had symptoms at rest, and she has had no palpitations. She takes hydrochlorothiazide for hypertension.

On physical examination, vitals are normal.. There is an early diastolic sound followed by a soft rumble heard best at the apex. S2 is normal.

An echocardiogram shows findings consistent **with moderate rheumatic mitral stenosis and minimal mitral regurgitation**. The mean gradient across the mitral valve is 8 mm Hg, and the **mitral valve area** is calculated to **be 1.8 cm<sup>2</sup>**. The mitral valve is pliable. **Moderate pulmonary hypertension** is present, with an estimated pulmonary artery systolic pressure of 45 mm Hg.

Which of the following is the most appropriate next step in management?

- A Exercise echocardiography
- B Medical therapy
- C Percutaneous balloon mitral valvuloplasty
- D Surgical mitral valve replacement

# QUESTION

A 45-year-old F is evaluated for a 12 mo history of exertional dyspnea. She experiences shortness of breath during mild exertion, such as house chores and walking on flat surfaces. She describes her symptoms as debilitating, as they have interfered with her activities of daily living. She has not had symptoms at rest, and she has had no palpitations. She takes hydrochlorothiazide for hypertension.

On physical examination, vitals are normal.. There is an early diastolic sound followed by a soft rumble heard best at the apex. S2 is normal.

An echocardiogram shows findings consistent with moderate rheumatic mitral stenosis and minimal mitral regurgitation. The mean gradient across the mitral valve is 8 mm Hg, and the mitral valve area is calculated to be 1.8 cm<sup>2</sup>. The mitral valve is pliable. Moderate pulmonary hypertension is present, with an estimated pulmonary artery systolic pressure of 45 mm Hg.

Which of the following is the most appropriate next step in management?

- A **Exercise echocardiography**
- B Medical therapy
- C Percutaneous balloon mitral valvuloplasty
- D Surgical mitral valve replacement

- A 32-year-old woman is evaluated for a prepregnancy assessment. She has a heart murmur but is asymptomatic. She has no history of atrial fibrillation. Her only medication is prenatal vitamins.
- On physical examination, blood pressure is 102/60 mm Hg and pulse rate is 70/min and regular. The estimated central venous pressure is elevated. The apical impulse is tapping, and there is a parasternal impulse at the left sternal border. The  $S_1$  and  $S_2$  are loud, and a grade 2/6 diastolic decrescendo murmur is heard at the apex. No opening snap is appreciated. The lungs are clear, and there is no edema.
- TTE demonstrates normal LV size and function. The mitral valve is thickened with diastolic doming. The mitral valve mean gradient is 12 mm Hg; the calculated mitral valve area is 0.9  $\text{cm}^2$ . There is no mitral valve regurgitation. The estimated pulmonary artery systolic pressure is 55 mm Hg.

Which of the following is the most appropriate management at this time?

- A. Initiate an ACE inhibitor and dabigatran
- B. Obtain cardiac magnetic resonance imaging
- C. Proceed with mitral valve intervention
- D. Proceed with pregnancy without interventions or testing



- A 32-year-old woman is evaluated for a **prepregnancy** assessment. She has a heart murmur but is asymptomatic. She has no history of atrial fibrillation. Her only medication is prenatal vitamins.
- On physical examination, blood pressure is 102/60 mm Hg and pulse rate is 70/min and regular. The estimated central venous pressure is elevated. The apical impulse is tapping, and there is a parasternal impulse at the left sternal border. **The S<sub>1</sub> and S<sub>2</sub> are loud, and a grade 2/6 diastolic decrescendo murmur is heard at the apex.** No opening snap is appreciated. The lungs are clear, and there is no edema.
- TTE demonstrates normal LV size and function. The mitral valve is thickened with diastolic doming. **The mitral valve mean gradient is 12 mmHg;** the calculated mitral valve area is **0.9 cm<sup>2</sup>.** There is no mitral valve regurgitation. **The estimated pulmonary artery systolic pressure is 55 mm Hg.**

Which of the following is the most appropriate management at this time?

- A. Initiate an ACE inhibitor and dabigatran
- B. Obtain cardiac magnetic resonance imaging
- C. Proceed with mitral valve intervention
- D. Proceed with pregnancy without interventions or testing

- A 32-year-old woman is evaluated for a prepregnancy assessment. She has a heart murmur but is asymptomatic. She has no history of atrial fibrillation. Her only medication is prenatal vitamins.
- On physical examination, blood pressure is 102/60 mm Hg and pulse rate is 70/min and regular. The estimated central venous pressure is elevated. The apical impulse is tapping, and there is a parasternal impulse at the left sternal border. The  $S_1$  and  $S_2$  are loud, and a grade 2/6 diastolic decrescendo murmur is heard at the apex. No opening snap is appreciated. The lungs are clear, and there is no edema.
- TTE demonstrates normal LV size and function. The mitral valve is thickened with diastolic doming. The mitral valve mean gradient is 12 mm Hg; the calculated mitral valve area is 0.9  $\text{cm}^2$ . There is no mitral valve regurgitation. The estimated pulmonary artery systolic pressure is 55 mm Hg.

Which of the following is the most appropriate management at this time?

- A. Initiate an ACE inhibitor and dabigatran
- B. Obtain cardiac magnetic resonance imaging
- C. Proceed with mitral valve intervention**
- D. Proceed with pregnancy without interventions or testing

# When to follow up

**Table 5. Frequency of Echocardiograms in Asymptomatic Patients With VHD and Normal LV Function**

Stage	Type of Valve Lesion			
	Aortic Stenosis*	Aortic Regurgitation	Mitral Stenosis	Mitral Regurgitation
Progressive (Stage B)	Every 3–5 y (mild severity; $V_{max}$ 2.0–2.9 m/s)	Every 3–5 y (mild severity)	Every 3–5 y (MV area >1.5 cm <sup>2</sup> )	Every 3–5 y (mild severity)
	Every 1–2 y moderate severity; $V_{max}$ 3.0–3.9 m/s)	Every 1–2 y (moderate severity)		Every 1–2 y (moderate severity)
Severe asymptomatic (Stage C1)	Every 6–12 mo ( $V_{max} \geq 4$ m/s)	Every 6–12 mo	Every 1–2 y (MV area 1.0–1.5 cm <sup>2</sup> )	Every 6–12 mo
		Dilating LV: More frequently	Every year (MV area <1.0 cm <sup>2</sup> )	Dilating LV: More frequently

Patients with mixed valve disease may require serial evaluations at intervals earlier than recommended for single-valve lesions. These intervals apply to most patients with each valve lesion and do not take into consideration the etiology of the valve disease.

\* With normal stroke volume.

LV indicates left ventricle; MV, mitral valve; VHD, valvular heart disease; and  $V_{max}$ , maximum velocity.

## Mitral Stenosis

Every 3–5 y (MV area  $>1.5$   $\text{cm}^2$ )

MILD-MOERATE MS

Every 1–2 y (MV area  $1.0$ – $1.5$   $\text{cm}^2$ ) Asymptomatic Severe MS

Every year (MV area  $<1.0$   $\text{cm}^2$ )  
Asymptomatic Very Severe MS

## Mitral Regurgitation

Every 3–5 y (mild severity)

Every 1–2 y (moderate severity)

Every 6–12 mo  
Asymptomatic Severe MR

Dilating LV: More frequently

# PERIODIC MONITORING= Surveillance TTE

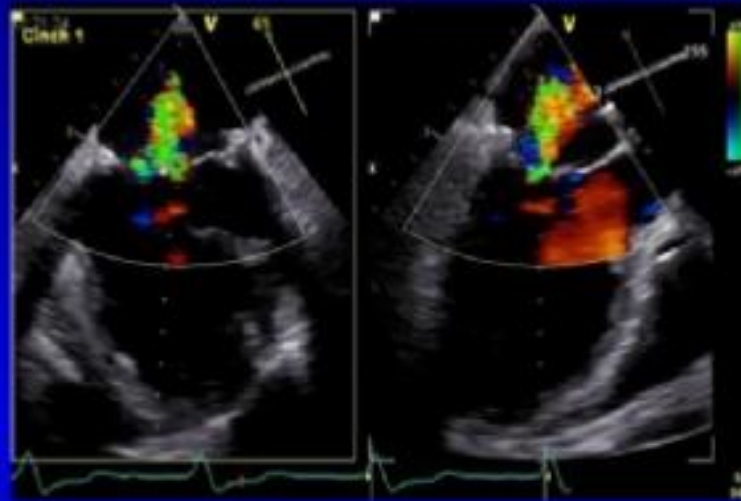
- In patients with **asymptomatic severe mitral regurgitation** with **preserved LV function** who do not have an indication for surgery → clinical and echocardiographic surveillance every **6 to 12 months is recommended**

# Mitral Regurgitation

1) Is the regurgitation severe ?

2) What is the mechanism of the regurgitation?

3) Is the patient symptomatic ?



4) Are there contraindications to any intervention on the valve ?

6) Is a transcatheter intervention feasible?

5) Is surgery contraindicated /high risk ?

7) What is the final decision of the heart team ?



# Mitral Regurgitation

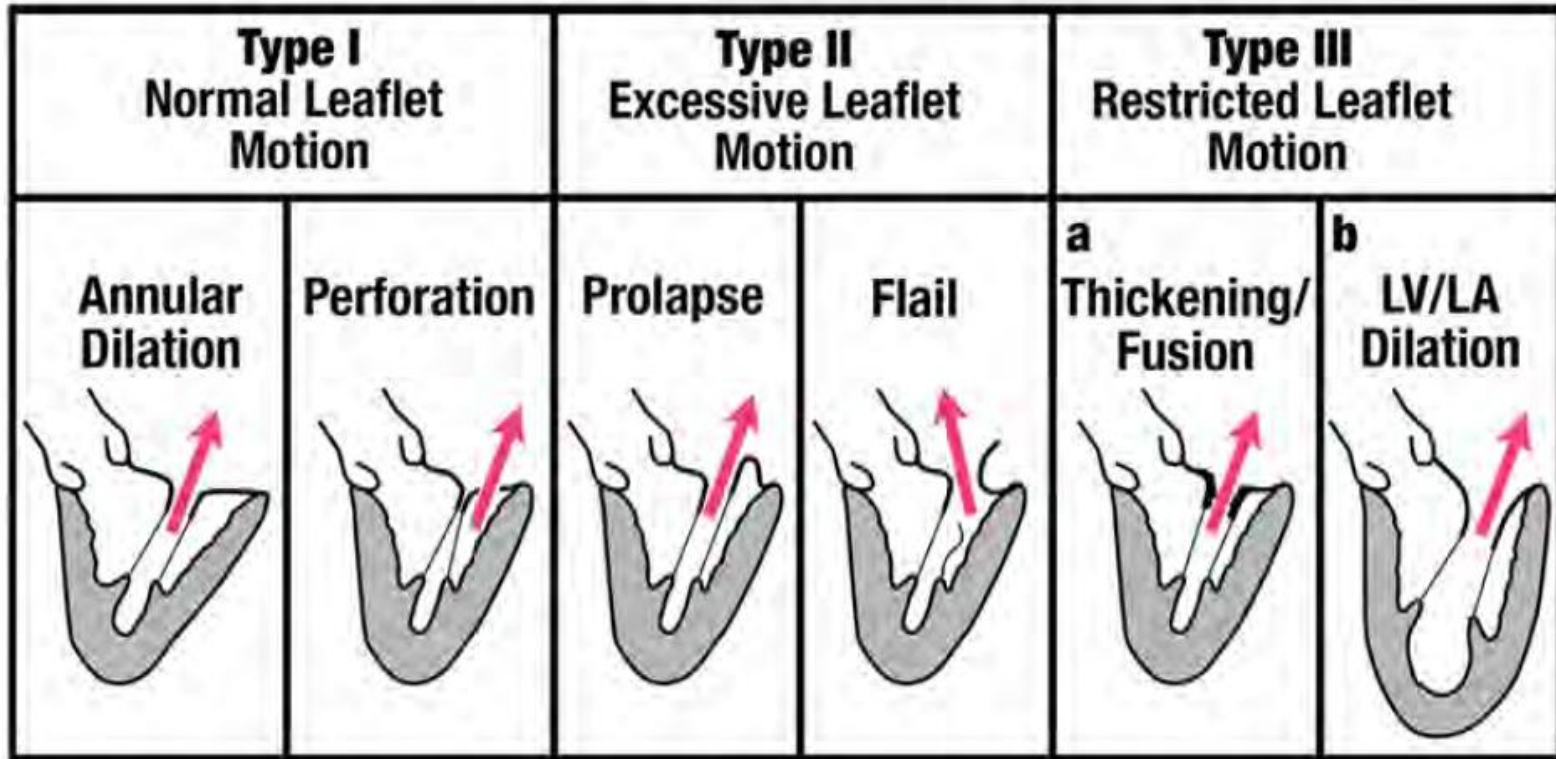
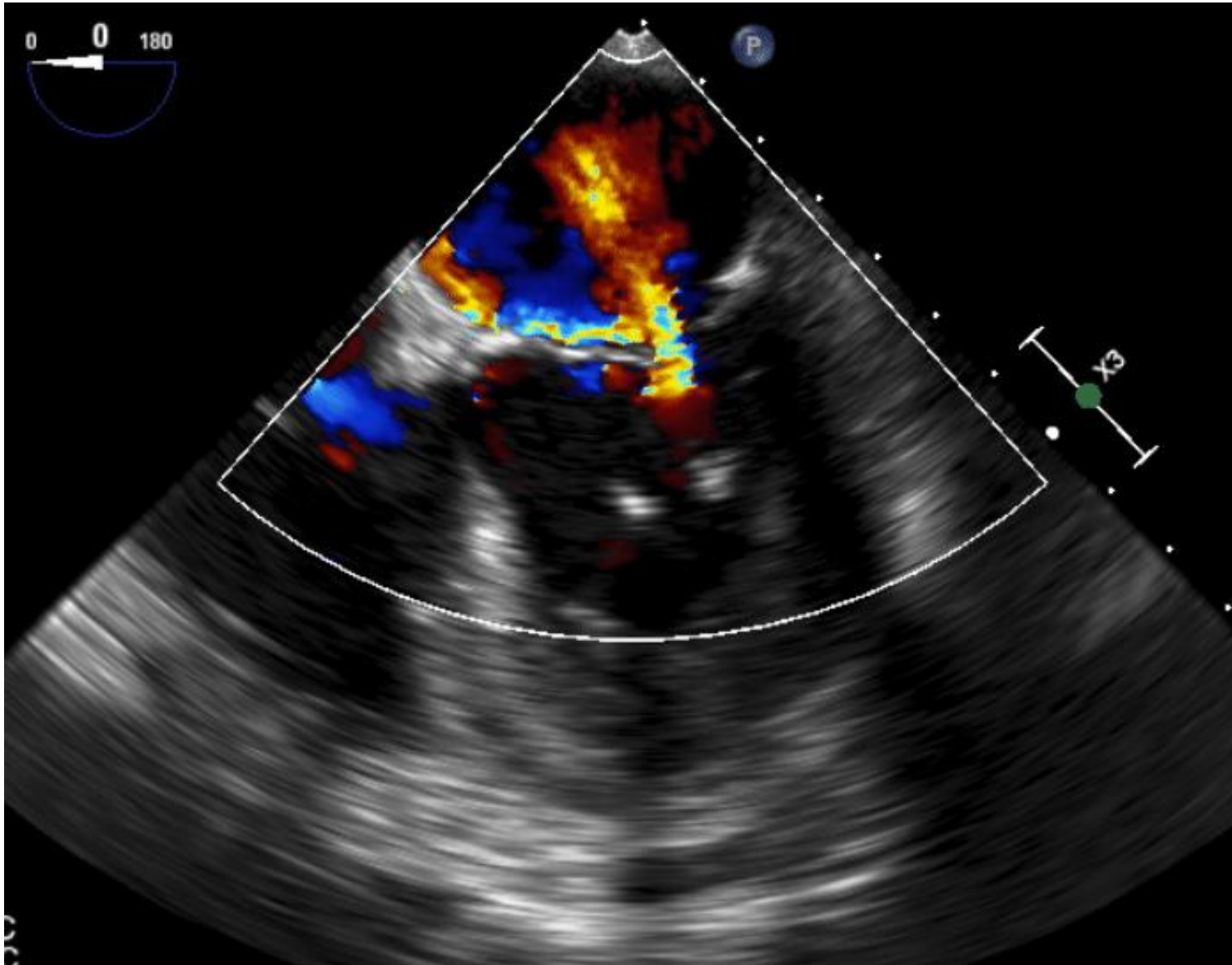


Figure 10 Depiction of mechanisms of MR as per the Carpentier classification.



# Severity of MR

1. **Color Doppler:** determining severity solely on this measure is **discouraged**.



2. **PW Doppler:** Mitral inflow and pulmonary veins PW Doppler can provide supportive elements.

In severe MR, peak mitral inflow velocity is typically  $>120$  cm/s.

Pulmonary venous flow is normally **antegrade** during both ventricular systole and diastole with a short **retrograde** flow during atrial systole.

With increasing MR, there is a **progressive blunting of the systolic component, with systolic flow reversal in cases of severe MR**.

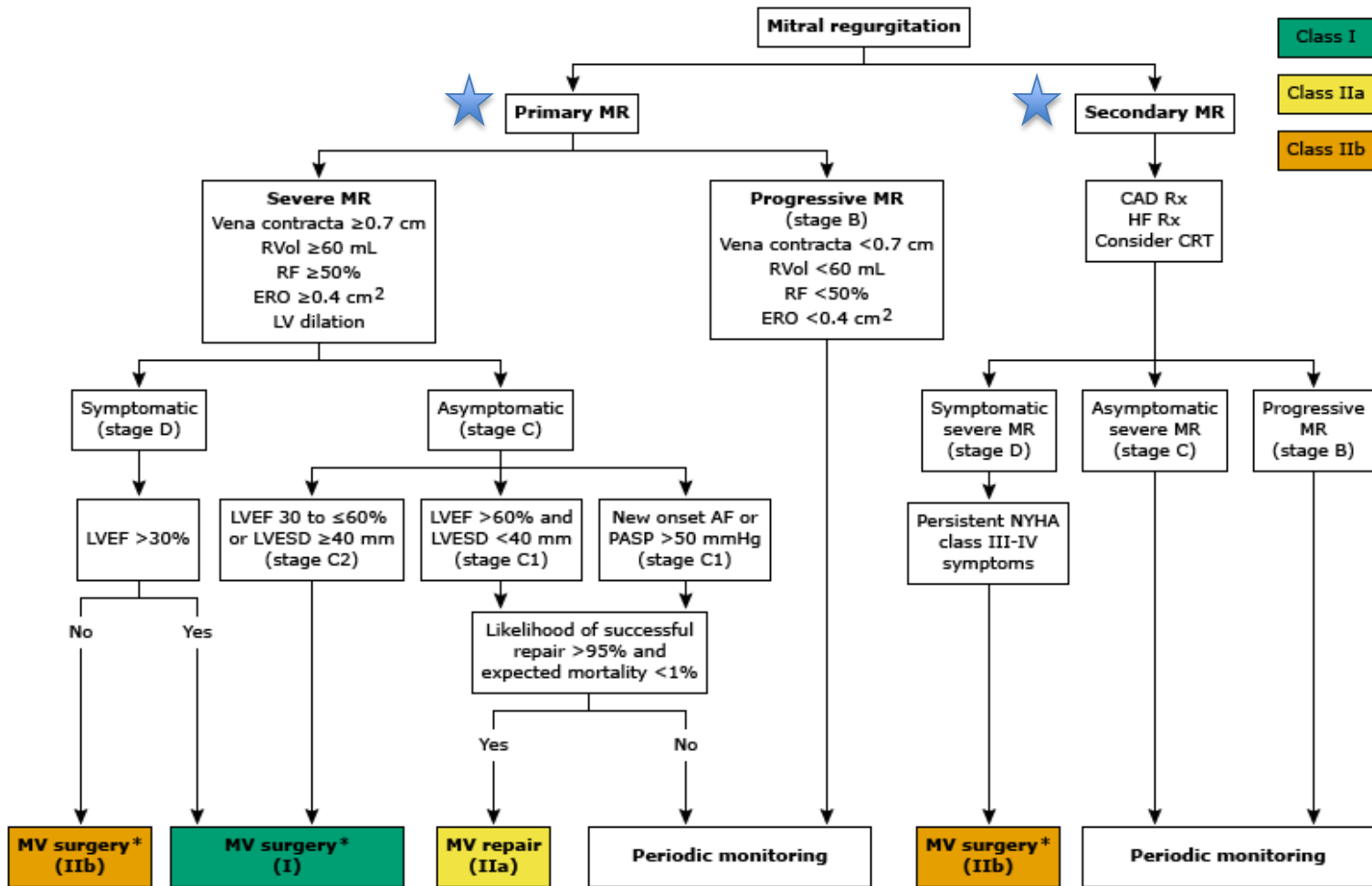
3. **CW Doppler:** A very dense jet supports severe MR

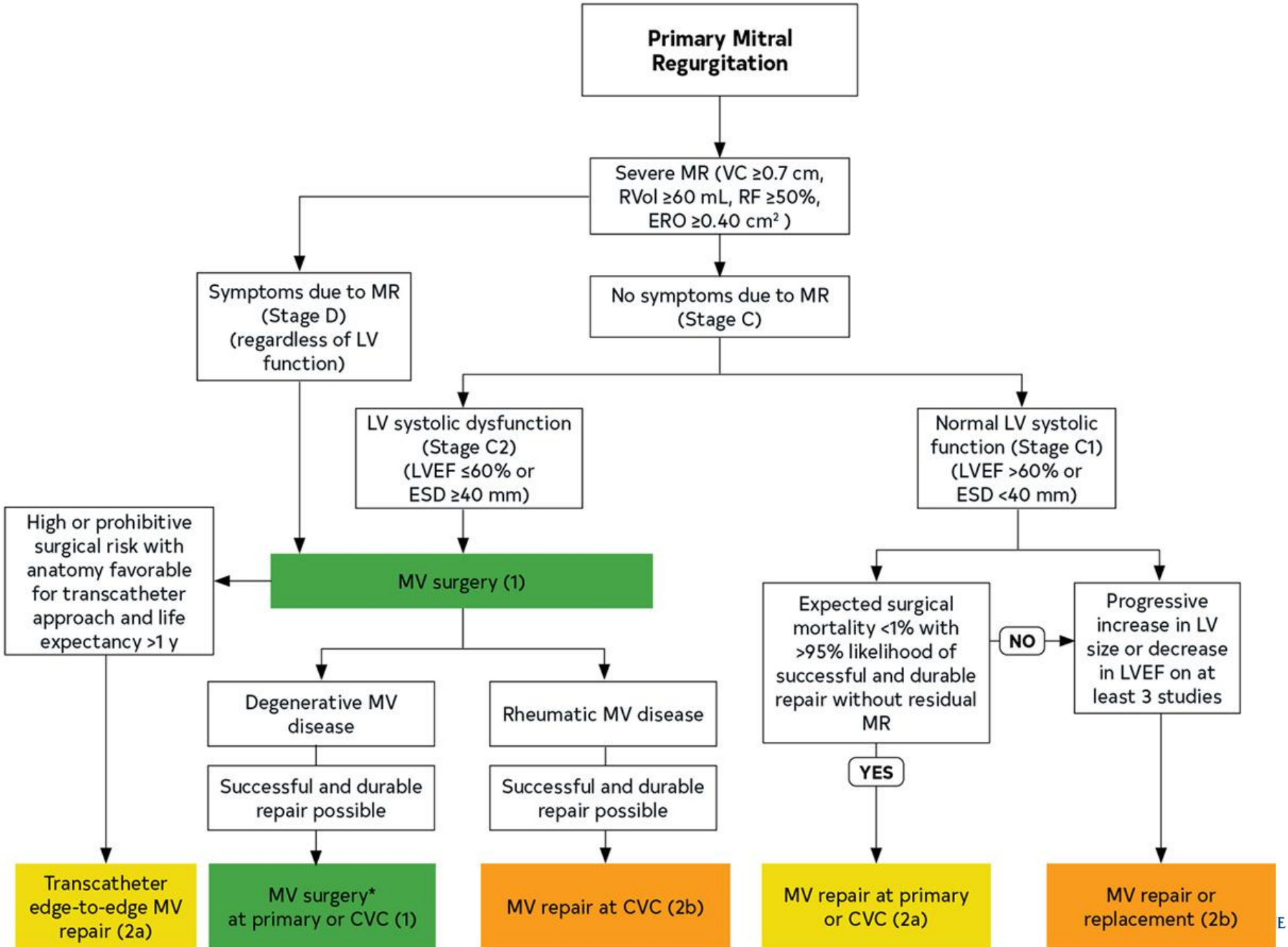
4. **PISA method:** when blood rushes through an orifice, it forms hemispheres with increasing velocity and decreasing surface area

Based on the continuity equation, the effective regurgitant orifice area, regurgitant volume and regurgitant fraction can be calculated.

# AHA GUIDELINES FOR SURGERY FOR MR

Surgical Indication	Strength
<u>Symptoms w/ LVEF &gt; 30%</u>	I
<u>Asymptomatic w/ LVEF between 30 - 60%</u>	I
<u>Asymptomatic with LVESD <math>\geq</math> 40 mm</u>	I
<u>Asymptomatic with new-onset Afib or Systolic PAP <math>\geq</math> 40 mmHg</u>	IIa
Asymptomatic with likelihood of successful and durable repair without >95% with an expected mortality <1% at a Heart Valve Center of Excellence	IIa
Asymptomatic patients with chronic severe primary MR (stage C1) and preserved LV function (LVEF >60% and LVESD <40 mm) with a progressive increase in LV size or decrease in EF on serial imaging studies	IIa





**Table 5. Frequency of Echocardiograms in Asymptomatic Patients With VHD and Normal LV Function**

Stage	Type of Valve Lesion			
	Aortic Stenosis*	Aortic Regurgitation	Mitral Stenosis	Mitral Regurgitation
Progressive (Stage B)	Every 3–5 y (mild severity; $V_{max}$ 2.0–2.9 m/s)	Every 3–5 y (mild severity)	Every 3–5 y (MV area >1.5 cm <sup>2</sup> )	Every 3–5 y (mild severity)
	Every 1–2 y moderate severity; $V_{max}$ 3.0–3.9 m/s)	Every 1–2 y (moderate severity)		Every 1–2 y (moderate severity)
Severe asymptomatic (Stage C1)	Every 6–12 mo ( $V_{max}$ ≥4 m/s)	Every 6–12 mo	Every 1–2 y (MV area 1.0–1.5 cm <sup>2</sup> )	Every 6–12 mo
		Dilating LV: More frequently	Every year (MV area <1.0 cm <sup>2</sup> )	Dilating LV: More frequently

Patients with mixed valve disease may require serial evaluations at intervals earlier than recommended for single-valve lesions. These intervals apply to most patients with each valve lesion and do not take into consideration the etiology of the valve disease.

\* With normal stroke volume.

LV indicates left ventricle; MV, mitral valve; VHD, valvular heart disease; and  $V_{max}$ , maximum velocity.

## Recommendation for Diagnostic Testing: Exercise Testing for Chronic Primary MR

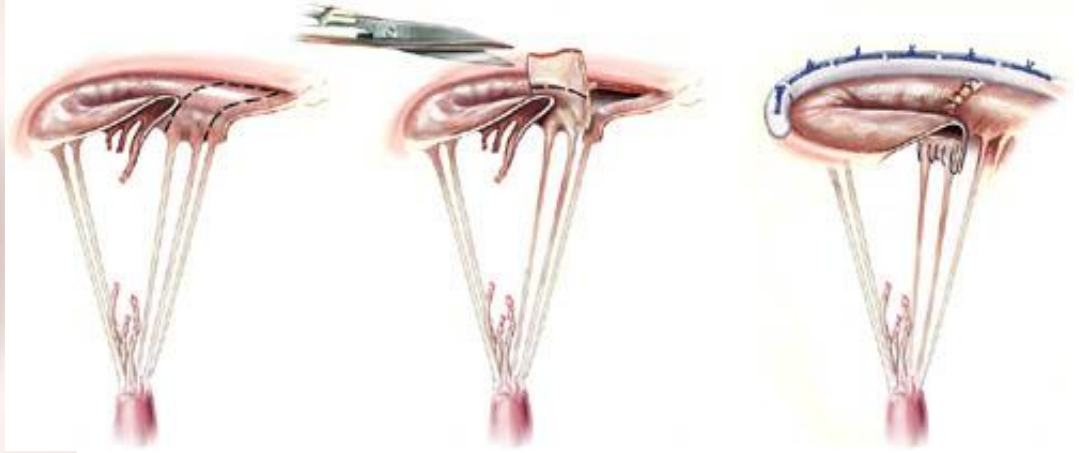
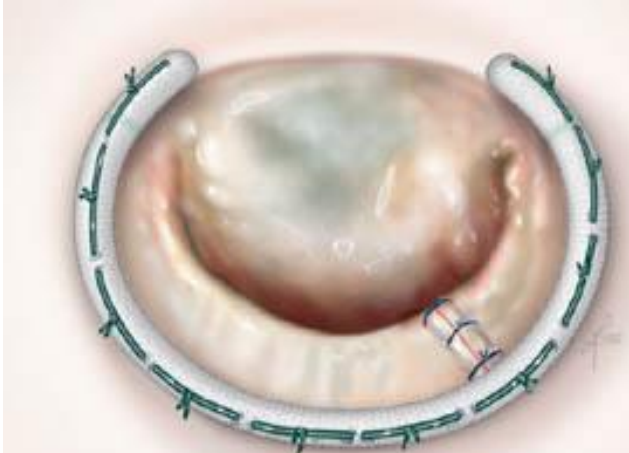
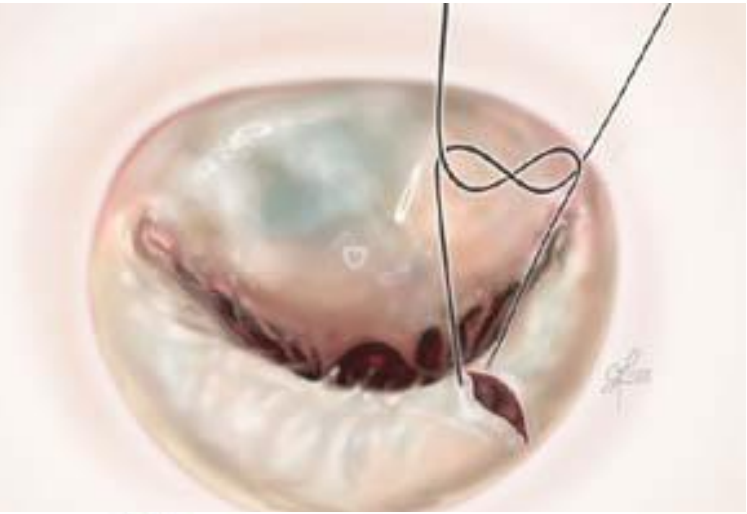
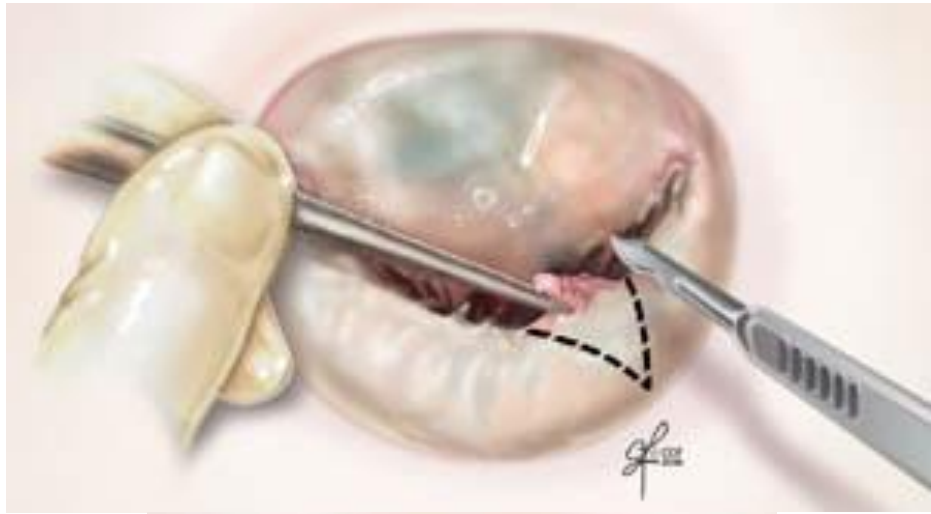Referenced studies that support the recommendation are summarized in [Online Data Supplement 28](#).

COR	LOE	Recommendation
2a	B-NR	1. In patients with primary MR (Stages B and C) and symptoms that might be attributable to MR, hemodynamic exercise testing using Doppler echocardiography or cardiac catheterization or cardiopulmonary exercise testing is reasonable. <sup>1-4</sup>



# Surgery vs Repair

- In general, **mitral valve repair** is preferred to valve replacement, as it is associated with improved survival in retrospective studies.
- Chordal preservation is preferred when replacement is needed, as it is associated with improved left ventricular geometry and long-term function.



# Features suggestive of successful MV repair



1. **Posterior** leaflet prolapse
2. Commissural prolapse
3. Rupture chordae to the **posterior** leaflet
4. Congenital cleft
5. Small perforation

# Question – MV regurgitation

A 26-year-old woman is evaluated during a visit to establish care. She has noted shortness of breath for the past 18 months that is progressively worsening. She has no significant medical history. She is active and exercises regularly. No meds

On physical examination, blood pressure is 115/70 mm Hg and pulse rate is 62/min. BMI is 45. Cardiac examination reveals a midsystolic click with a grade 3/6 late systolic murmur heard over the apex and radiating toward the axilla.

TTE shows moderate to severe mitral regurgitation with marked prolapse of the anterior leaflet, normal left ventricular systolic function with an EF of **55%**, and normal chamber sizes; the regurgitant jet is not well visualized.

**Which of the following is the most appropriate management?**

- A. Mitral valve repair
- B. Repeat TTE in 6 months
- C. Start lisinopril
- D. Transesophageal echocardiography

# Question – MV regurgitation

A 26-year-old woman is evaluated during a visit to establish care. She has noted **shortness of breath for the past 18 months** that is progressively worsening. She has no significant medical history. She is active and exercises regularly. No meds

On physical examination, blood pressure is 115/70 mm Hg and pulse rate is 62/min. BMI is 45. Cardiac examination reveals **a midsystolic click with a grade 3/6 late systolic murmur heard** over the apex and radiating toward the axilla.

TTE shows **moderate to severe mitral regurgitation with marked prolapse of the anterior leaflet**, normal left ventricular systolic function with an EF of 55%, and normal chamber sizes; **the regurgitant jet is not well visualized.**

**Which of the following is the most appropriate management?**

- A. Mitral valve repair
- B. Repeat TTE in 6 months
- C. Start lisinopril
- D. Transesophageal echocardiography

# Question – MV regurgitation

A 26-year-old woman is evaluated during a visit to establish care. She has noted shortness of breath for the past 18 months that is progressively worsening. She has no significant medical history. She is active and exercises regularly. No meds


On physical examination, blood pressure is 115/70 mm Hg and pulse rate is 62/min. BMI is 45. Cardiac examination reveals a midsystolic click with a grade 3/6 late systolic murmur heard over the apex and radiating toward the axilla.

TTE shows moderate to severe mitral regurgitation with marked prolapse of the anterior leaflet, normal left ventricular systolic function with an EF of **55%**, and normal chamber sizes; the regurgitant jet is not well visualized.

**Which of the following is the most appropriate management?**

- A. Mitral valve repair
- B. Repeat TTE in 6 months
- C. Start lisinopril
- D. Transesophageal echocardiography**

# 30-40-50-60 ?



First Year

- 30 LVEF > 30%
- 40 LVESD  $\geq$  40 mm
- 50 RVSP  $\geq$  50 mmHg
- 60 LVEF < 60%

## Indications for repair

# Question – MV regurgitation

A 77-year-old man is evaluated during a routine examination.

No medical Hx. He is active and exercises regularly. He does not take any medications.

On physical examination, blood pressure is 135/70 mm Hg, pulse rate is 82/min, and respiration rate is 17/min. Cardiac examination reveals a grade 3/6 apical holosystolic murmur.

Echocardiogram shows severe mitral regurgitation and LVEF 45%

Which of the following is the most appropriate management?

- A Vasodilator therapy
- B Percutaneous mitral balloon valvuloplasty
- C Repeat echocardiogram in 6 months
- D. Surgical mitral valve repair



# Question – MV regurgitation

A 77-year-old man is evaluated during a routine examination.

**No medical Hx. He is active and exercises regularly.** He does not take any medications.

On physical examination, blood pressure is 135/70 mm Hg, pulse rate is 82/min, and respiration rate is 17/min. Cardiac examination reveals a grade 3/6 apical holosystolic murmur.

Echocardiogram shows **severe mitral regurgitation and LVEF 45%**

Which of the following is the most appropriate management?

- A Vasodilator therapy
- B Percutaneous mitral balloon valvuloplasty
- C Repeat echocardiogram in 6 months
- D. Surgical mitral valve repair

# Question – MV regurgitation

A 77-year-old man is evaluated during a routine examination.

No medical Hx. He is active and exercises regularly. He does not take any medications.

On physical examination, blood pressure is 135/70 mm Hg, pulse rate is 82/min, and respiration rate is 17/min. Cardiac examination reveals a grade 3/6 apical holosystolic murmur.

Echocardiogram shows severe mitral regurgitation and LVEF 45%

Which of the following is the most appropriate management?

A Vasodilator therapy

B Percutaneous mitral balloon valvuloplasty

C Repeat echocardiogram in 6 months

**D. Surgical mitral valve repair**

# Question – MV regurgitation

A 67-year-old woman is evaluated during a routine examination. She was diagnosed with a cardiac murmur in early adulthood.

She is active, healthy, and without symptoms. She takes no medications.

On physical examination, vital signs are normal.

Besides a grade 3/6 holosystolic murmur preceded by multiple clicks at apex, the physical findings are unremarkable.

A TTE shows LV EF of 50% and end-systolic dimension of LV is 42 mm. Myxomatous degeneration of the mitral valve is present with severe regurgitation due to posterior leaflet prolapse.

Which of the following is the most appropriate next step in management?

- A Serial clinical and echocardiographic evaluations
- B Surgical mitral valve repair
- C Surgical mitral valve replacement
- D Transcatheter mitral valve repair

# Question – MV regurgitation

A 67-year-old woman is evaluated during a routine examination. She was diagnosed with a cardiac murmur in early adulthood.

**She is active, healthy, and without symptoms.** She takes no medications.

On physical examination, vital signs are normal.

Besides a grade 3/6 holosystolic murmur preceded by multiple clicks at apex, the physical findings are unremarkable.

A TTE shows LV EF of 50% and **end-systolic dimension of LV is 42 mm.**  
**Myxomatous degeneration of the mitral valve is present with severe regurgitation due to posterior leaflet prolapse.**

Which of the following is the most appropriate next step in management?

- A Serial clinical and echocardiographic evaluations
- B Surgical mitral valve repair
- C Surgical mitral valve replacement
- D Transcatheter mitral valve repair

# Question – MV regurgitation

A 67-year-old woman is evaluated during a routine examination. She was diagnosed with a cardiac murmur in early adulthood.

She is active, healthy, and without symptoms. She takes no medications.

On physical examination, vital signs are normal.

Besides a grade 3/6 holosystolic murmur preceded by multiple clicks at apex, the physical findings are unremarkable.

A TTE shows LV EF of 50% and end-systolic dimension of LV is 42 mm. Myxomatous degeneration of the mitral valve is present with severe regurgitation due to posterior leaflet prolapse.

Which of the following is the most appropriate next step in management?

- A Serial clinical and echocardiographic evaluations
- B Surgical mitral valve repair**
- C Surgical mitral valve replacement
- D Transcatheter mitral valve repair

# Question – MV regurgitation

An 87-year-old woman is hospitalized for acute decompensated heart failure.

PMHx significant for a stroke 4 years ago, hypertension, severe COPD, and CKD III

She underwent diuresis with furosemide overnight and is now resting comfortably.

Home meds: lisinopril, atorvastatin, low-dose aspirin, tiotropium, and as-needed albuterol.

Vitals: temperature is normal, blood pressure is 95/65 mm Hg, pulse rate is 80/min, and RR is normal. Oxygen sat 90% on 2 L O<sub>2</sub> per NC.

Bilateral crackles are noted in the bottom quarter of the lung fields. The estimated central venous pressure is elevated. S<sub>1</sub> is diminished. A grade 3/6 holosystolic murmur and soft diastolic rumble are present at the apex.

TTE shows a flail segment involving the posterior leaflet of the mitral valve and severe regurgitation. The left ventricular ejection fraction is 60%.

Cardiac and pulmonary surgical risks are estimated to be high (estimated operative mortality, 10%).

What is the most appropriate next step?

- A Mitral valve replacement
- B Surgical mitral valve repair
- C Transcatheter mitral valve repair
- D Continue current medical therapy

# Question – MV regurgitation

An 87-year-old woman is hospitalized for acute decompensated heart failure.

PMHx significant for a stroke 4 years ago, hypertension, severe COPD, and CKD III

She underwent diuresis with furosemide overnight and is now resting comfortably.

Home meds: lisinopril, atorvastatin, low-dose aspirin, tiotropium, and as-needed albuterol.

Vitals: temperature is normal, blood pressure is 95/65 mm Hg, pulse rate is 80/min, and RR is normal. Oxygen sat 90% on 2 L O<sub>2</sub> per NC.

Bilateral crackles are noted in the bottom quarter of the lung fields. The estimated central venous pressure is elevated. S<sub>1</sub> is diminished. A grade 3/6 holosystolic murmur and soft diastolic rumble are present at the apex.

TTE shows a flail segment involving the posterior leaflet of the mitral valve and severe regurgitation. The left ventricular ejection fraction is 60%.

Cardiac and pulmonary surgical risks are estimated to be high (estimated operative mortality, 10%).

What is the most appropriate next step?

- A Mitral valve replacement
- B Surgical mitral valve repair
- C Transcatheter mitral valve repair
- D Continue current medical therapy

# Question – MV regurgitation

An 87-year-old **woman is hospitalized for acute decompensated heart failure.**

PMHx significant for a stroke 4 years ago, hypertension, severe COPD, and CKD III

She underwent diuresis with furosemide overnight and is now resting comfortably.

Home meds: lisinopril, atorvastatin, low-dose aspirin, tiotropium, and as-needed albuterol.

Vitals: temperature is normal, blood pressure is 95/65 mm Hg, pulse rate is 80/min, and RR is normal. Oxygen sat 90% on 2 L O<sub>2</sub> per NC.

**Bilateral crackles** are noted in the bottom quarter of the lung fields. The estimated central venous pressure is elevated. S1 is diminished. A grade 3/6 holosystolic murmur and soft diastolic rumble are present at the apex.

**TTE shows a flail segment involving the posterior leaflet of the mitral valve and severe regurgitation.** The left ventricular ejection fraction is 60%.

Cardiac and pulmonary surgical risks are estimated to be **high (estimated operative mortality, 10%).**

What is the most appropriate next step?

- A Mitral valve replacement
- B Surgical mitral valve repair
- C Transcatheter mitral valve repair
- D Continue current medical therapy



# Question – MV regurgitation

An 87-year-old woman is hospitalized for acute decompensated heart failure.

PMHx significant for a stroke 4 years ago, hypertension, severe COPD, and CKD III

She underwent diuresis with furosemide overnight and is now resting comfortably.

Home meds: lisinopril, atorvastatin, low-dose aspirin, tiotropium, and as-needed albuterol.

Vitals: temperature is normal, blood pressure is 95/65 mm Hg, pulse rate is 80/min, and RR is normal. Oxygen sat 90% on 2 L O<sub>2</sub> per NC.

Bilateral crackles are noted in the bottom quarter of the lung fields. The estimated central venous pressure is elevated. S<sub>1</sub> is diminished. A grade 3/6 holosystolic murmur and soft diastolic rumble are present at the apex.

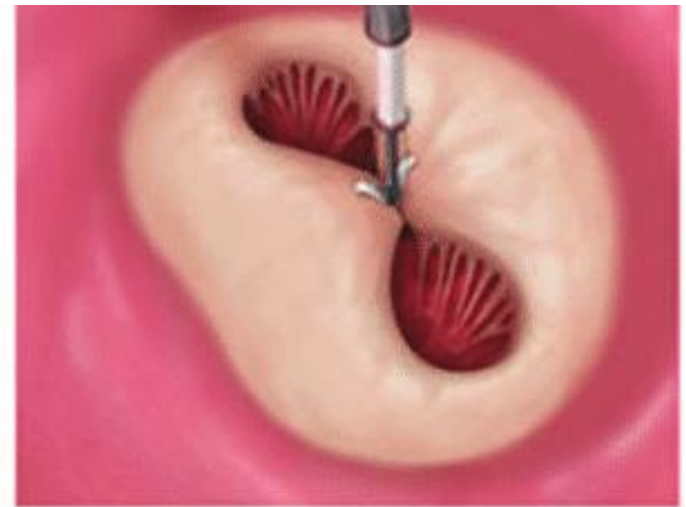
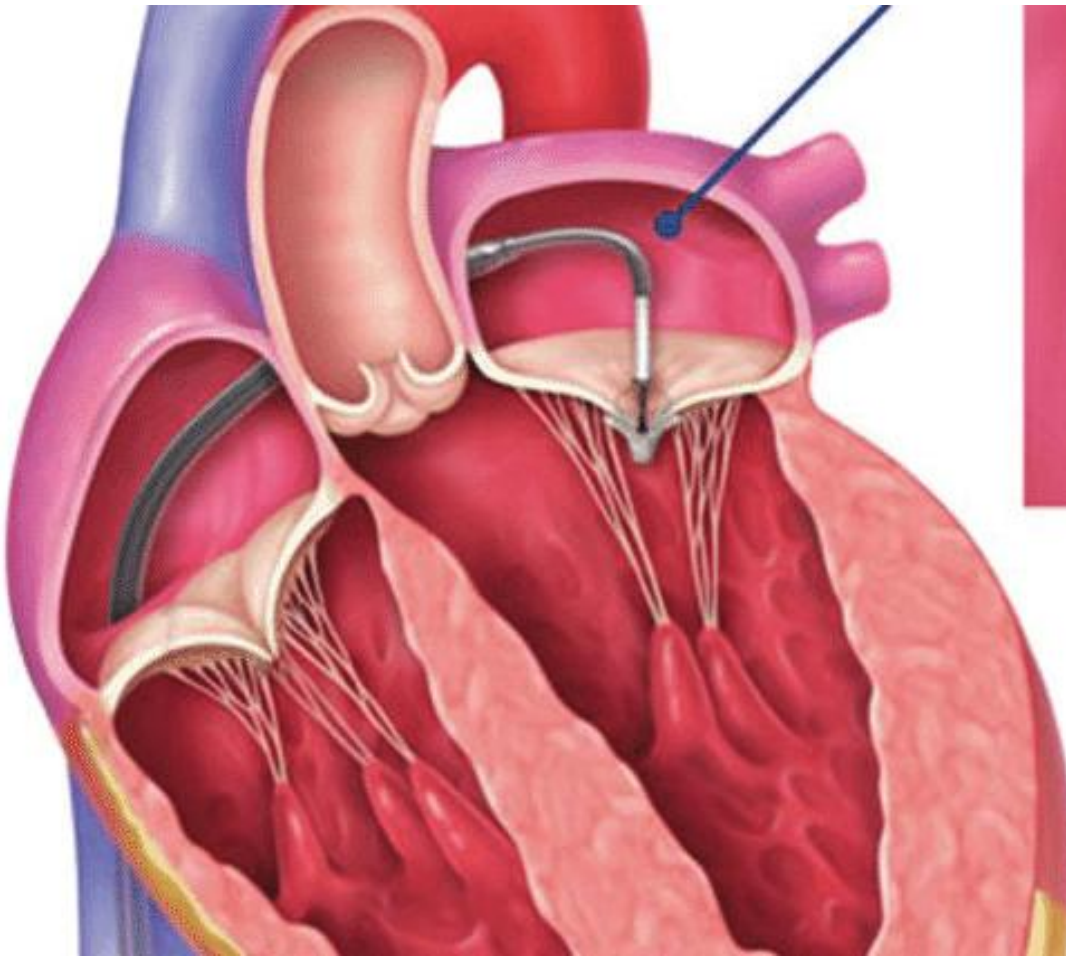
TTE shows a flail segment involving the posterior leaflet of the mitral valve and severe regurgitation. The left ventricular ejection fraction is 60%.

Cardiac and pulmonary surgical risks are estimated to be high (estimated operative mortality, 10%).

What is the most appropriate next step?

- A Mitral valve replacement
- B Surgical mitral valve repair
- C Transcatheter mitral valve repair**
- D Continue current medical therapy

# MitraClip



Atrial view

# MitraClip

- Until 2018, transcatheter mitral valve repair, was indicated for symptomatic patients with **primary degenerative mitral regurgitation** who are at **prohibitive surgical risk**, such as this patient.
- With this technique, the mitral valve is plicated using an approach from the femoral vein

## News & Events

Home > News & Events > Newsroom > Press Announcements

### FDA News Release

# FDA approves new indication for valve repair device to treat certain heart failure patients with mitral regurgitation

[f SHARE](#) [TWEET](#) [in LINKEDIN](#) [PIN IT](#) [EMAIL](#) [PRINT](#)

For Immediate

March 14, 2019

# Bonus Question

A 26-year-old woman with a mechanical mitral valve prosthesis placed 5 years prior who visits to discuss anticoagulation management during pregnancy

Meds: low-dose aspirin, metoprolol, and warfarin (4 mg/d).

On physical examination, Vitals normal. Cardiac auscultation demonstrates a normal mechanical S<sub>1</sub>. There are no murmurs or added sounds. INR is 2.6.

Which of the following anticoagulation regimens will provide the greatest protection against thromboembolism during her pregnancy?

- A. Continue warfarin and aspirin
- **B. Stop warfarin and start dabigatran**
- C. Stop warfarin and start subcutaneous fixed-dose unfractionated heparin
- D. Stop warfarin and start weight-based low-molecular-weight heparin

# Bonus Question

A 26-year-old woman with a mechanical mitral valve prosthesis placed 5 years prior who visits to discuss anticoagulation management during pregnancy

Meds: low-dose aspirin, metoprolol, and warfarin (4 mg/d).

On physical examination, Vitals normal. Cardiac auscultation demonstrates a normal mechanical S<sub>1</sub>. There are no murmurs or added sounds. INR is 2.6.

Which of the following anticoagulation regimens will provide the greatest protection against thromboembolism during her pregnancy?

- **A. Continue warfarin and aspirin**
- **B. Stop warfarin and start dabigatran**
- **C. Stop warfarin and start subcutaneous fixed-dose unfractionated heparin**
- **D. Stop warfarin and start weight-based low-molecular-weight heparin**

# BONUS QUESTION 2

A 72-year-old woman is evaluated in the hospital for a 3-month history of increasing shortness of breath. Medications are chlorthalidone and atorvastatin.

On physical examination, the patient is afebrile, blood pressure is 140/70 mm Hg, pulse rate is 83/min, and respiratory rate is 16/min. Oxygen saturation breathing ambient air is 98%. There is no jugular venous distention. Lungs are clear. Cardiac examination reveals a regular rate and a grade 3/6 apical holosystolic murmur that radiates to the axilla. There is no lower extremity edema.

EKG : NSR WITH LAD.

TTE ssevere eccentric mitral regurgitation with marked calcification of the valve leaflets; left ventricular systolic function is normal.

Which of the following is the most appropriate treatment?

- A Bioprosthetic mitral valve replacement
- B Mechanical mitral valve replacement
- C. Oral vasodilator therapy
- D Percutaneous mitral valvuloplasty

# BONUS QUESTION 2

A 72-year-old woman is evaluated in the hospital for a 3-month history of increasing shortness of breath. Medications are chlorthalidone and atorvastatin.

On physical examination, the patient is afebrile, blood pressure is 140/70 mm Hg, pulse rate is 83/min, and respiratory rate is 16/min. Oxygen saturation breathing ambient air is 98%. There is no jugular venous distention. Lungs are clear. Cardiac examination reveals a regular rate and a grade 3/6 apical holosystolic murmur that radiates to the axilla. There is no lower extremity edema.

EKG : NSR WITH LAD.

TTE ssevere eccentric mitral regurgitation with marked calcification of the valve leaflets; left ventricular systolic function is normal.

Which of the following is the most appropriate treatment?

- A Bioprosthetic mitral valve replacement**
- B Mechanical mitral valve replacement**
- C. Oral vasodilator therapy**
- D Percutaneous mitral valvuloplasty**



# Resources

1. “Mitral Valve Repair Procedure Details.” Clevelandclinic.org, 14 Dec. 2018, [my.clevelandclinic.org/health/treatments/17240-mitral-valve-repair/resources](https://my.clevelandclinic.org/health/treatments/17240-mitral-valve-repair/resources).
2. “Medical Knowledge Self-Assessment Program.” ACP, 2016, [mksap17.acponline.org/app/groups/cv/topics/](https://mksap17.acponline.org/app/groups/cv/topics/).
3. “Medical Knowledge Self-Assessment Program.” ACP, 2018, [mksap18.acponline.org/app/dashboard](https://mksap18.acponline.org/app/dashboard)
4. Harb SC, Griffin BP. Mitral Valve Disease: a Comprehensive Review. Curr Cardiol Rep 2017;19:73  
[10.1007/s11886-017-0883-5](https://doi.org/10.1007/s11886-017-0883-5)
5. Vahanian, Alec. “Expert Review: Mitral Valve Disease.” European Society of Cardiology, 23 Jan. 2019, [www.escardio.org/Journals/E-Journal-of-Cardiology-Practice/Volume-16/Expert-review-mitral-valve-disease](http://www.escardio.org/Journals/E-Journal-of-Cardiology-Practice/Volume-16/Expert-review-mitral-valve-disease).