

Rheumatology Jeopardy

Disease of
Kings

Alphabet
Soup

The Lost
Art

Medication
Misadventures

Potpourri

\$100

\$100

\$100

\$100

\$100

\$200

\$200

\$200

\$200

\$200

\$300

\$300

\$300

\$300

\$300

\$400

\$400

\$400

\$400

\$400

\$500

\$500

\$500

\$500

\$500

About Gout! - \$100

Q: Confirmation of these crystals on polarized microscopy is the gold standard for diagnosis of gout.

A: Monosodium urate crystals



About Gout! - \$200

Q: Three associated features of allopurinol hypersensitivity syndrome

A: Asian race, kidney disease, and HLA-B*5801 gene



About Gout! - \$300

Q: The 2016 European League Against Rheumatism (EULAR) recommendations support a “treat-to-target” approach reducing the serum urate level to what in patients without tophi and what in patients with tophi.

A: Urate level to less than 6.0 mg/dL (0.35 mmol/L) in patients without tophi and less than 5.0 mg/dL (0.30 mmol/L) in patients with tophi.



About Gout! - \$400

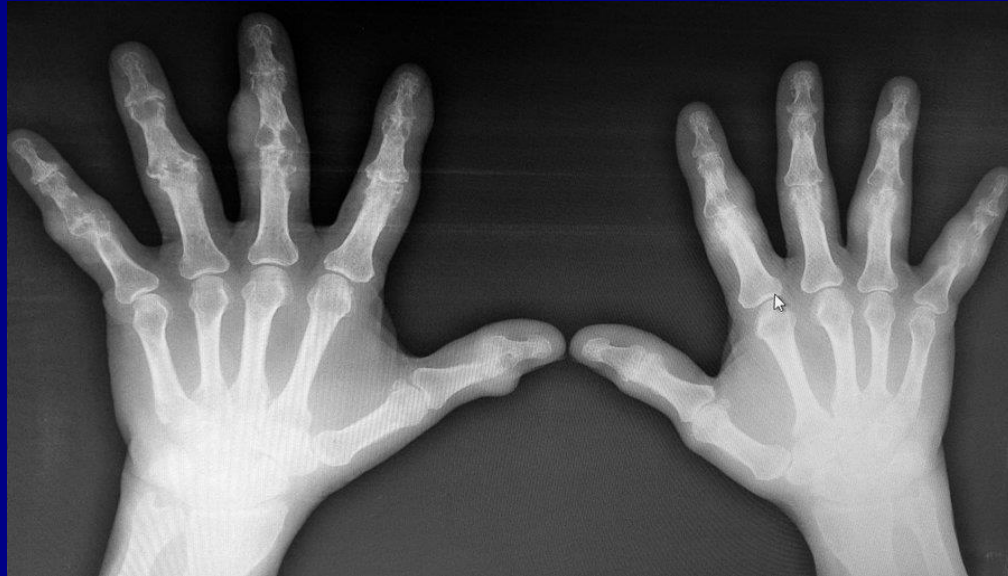Q: What medication can be used for acute refractory gout?

A: Anakinra



About Gout - \$500

Q: What are the plain radiographic findings characteristic of gout?



A: subcortical cysts, punched out erosions with sclerotic margins in a marginal and juxta-articular distribution.



Alphabet Soup - \$100

Q: This autoantibody is sensitive for the diagnosis of lupus, but lacks specificity and does not correlate with disease activity.

A: What is ANA



Alphabet Soup - \$200

Q: This autoantibody is useful for the monitoring of disease activity in lupus.

A: What is anti-DS DNA



Alphabet Soup - \$300

Q: This autoantibody has high sensitivity for mixed connective tissue disease.

A: What is Anti-U1-RNP



Alphabet Soup - \$400

Q: Patients with limited cutaneous systemic sclerosis and this antibody are more likely to develop pulmonary arterial hypertension.

**A: What is
anticentromere**



Alphabet Soup - \$500

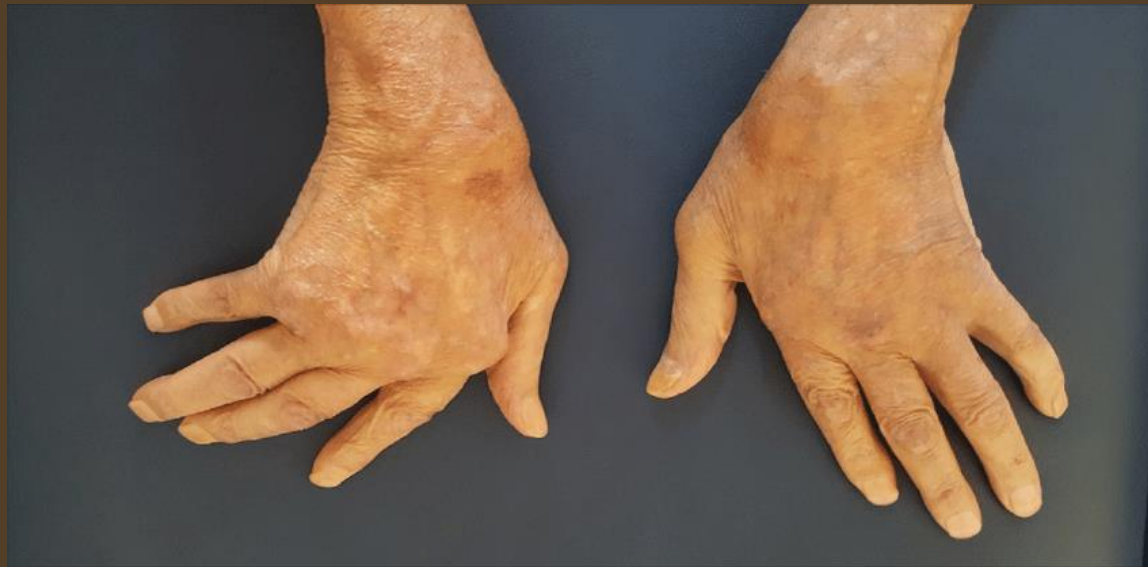Q: This antibody is seen in patients with diffuse cutaneous systemic sclerosis who have pulmonary fibrosis.

A: What is anti-ScI-70



The Exam - \$100

Q: Most common inflammatory arthritis associated with this hand deformity.

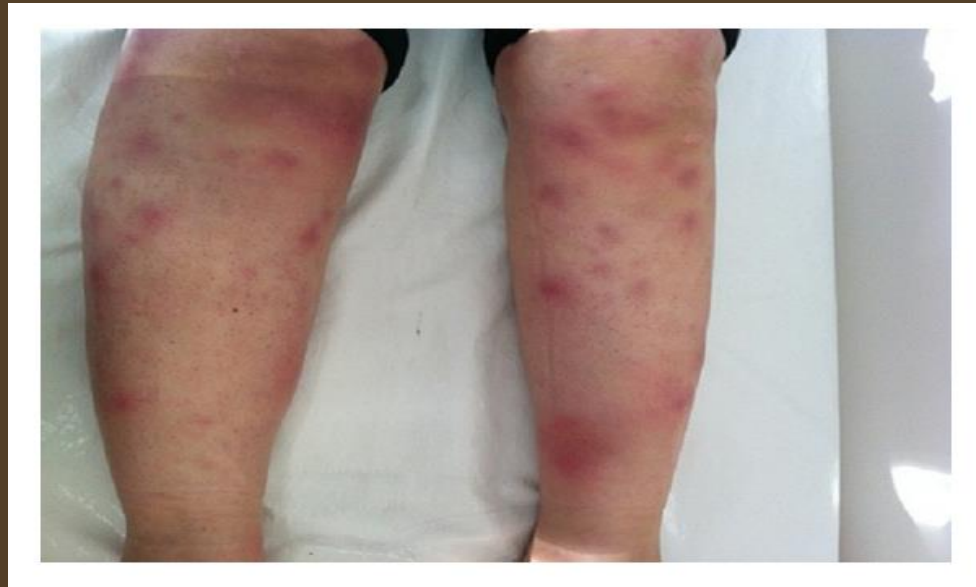

A: Rheumatoid arthritis



The Exam - \$200

Q: A patient presents with bilateral ankle pain and the following rash, what is the next test you order to rule out what disease(s)?

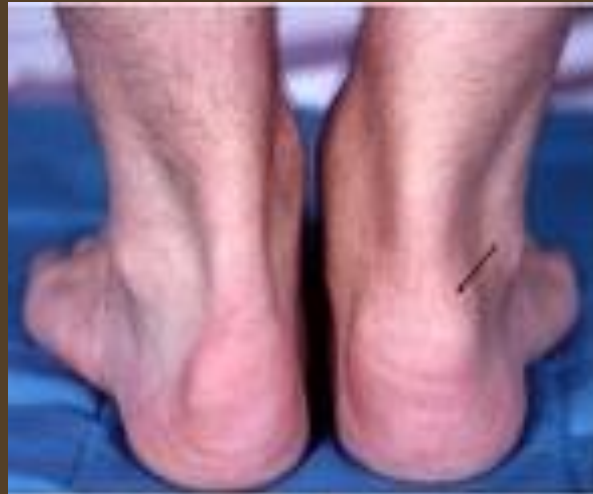

**A: Chest xray, Lofgren syndrome
(or coccidioidomycosis/histo)**



The Exam - \$300

Q: This is a common physical exam finding in Psoriatic arthritis.



A: Enthesitis, the hallmark of seronegative spondyarthropathies



The Exam - \$400

Q: The presence of subclavian bruits supports this diagnosis.

A: Giant cell arteritis



The Exam - \$500

Q: Your patient refuses further blood draws due to tender nodule formation after each needle stick. What disease are you suspicious for and the name of the phenomena?

A: Behcet's diseases and the pathergy skin test.



Side Effects- \$100

Q: List 3 side effects of corticosteroids.

A: Avascular necrosis, hyperglycemia, myopathy, glaucoma, osteoporosis, immunosuppression, skin fragility, cataracts, weight gain, HTN, psychomotor agitation, HPA axis suppression



Side Effects - \$200

Q: Recommendations for ophthalmological surveillance for hydroxychloroquine?

**A: Baseline fundoscopic exam,
follow up screening annually
every 5 years.**



Side Effects - \$300

Q: Prior to initiating a TNF – alpha inhibitor, what must you do?

A: Screen for TB/HBV/HIV and VZV and immunize appropriately.



Side Effects - \$400

Q: This medication used in combination or alone for RA and IBD-associated arthritis can cause reversible azospermia.

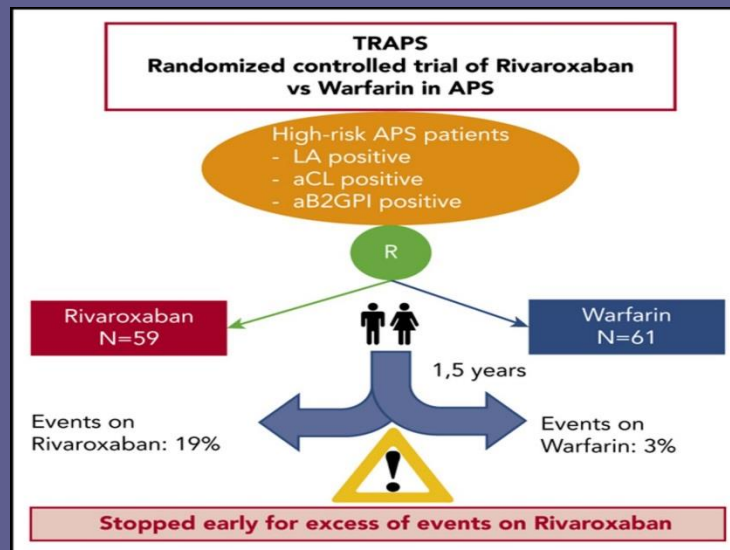
A: Sulfasalazine



Side Effects - \$500

Q: This trial was stopped early in 2018, and this became the preferred method of anticoagulation for antiphospholipid syndrome. (trial and drug)

A: Warfarin, 2018 TRAPS trial



Potpourri - \$100

Q: This is the major cause of excess death in patients with RA

A: What is atherosclerotic heart disease



Potpourri - \$200

Q: This class of drugs can precipitate a scleroderma renal crisis.

A: What are corticosteroids



Potpourri - \$300

Q: This class of drugs is used to treat scleroderma renal crisis.

A: What are ace inhibitors?



Potpourri - \$400

Q: This is the dose of prednisone you start when you suspect giant cell arteritis in a patient with no vision complaints.

A: 1 mg/kg, up to 60 mg daily



Potpourri - \$500

Q: These are two cutaneous pathognomonic features of dermatomyositis.

A: Gottron papules and heliotrope rash

