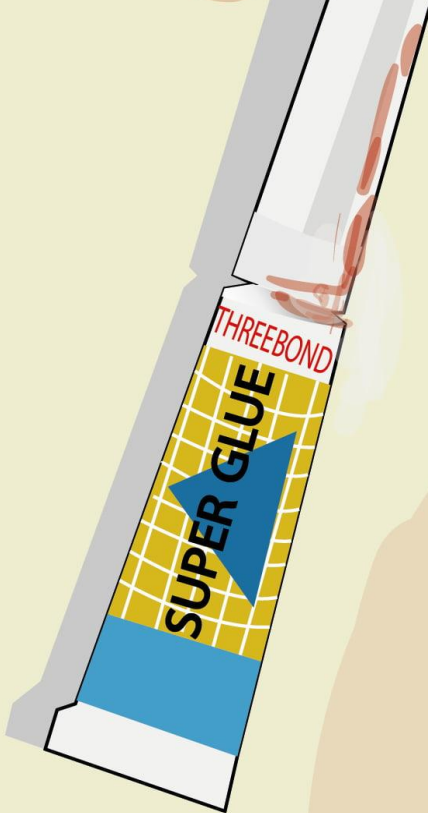


# JEOPARDY!



## Musical Valves

\$100

\$200

\$300

\$400

## Songs from the Heart

\$100

\$200

\$300

\$400

## My Heart Isn't Defective

\$100

\$200

\$300

\$400


## Wild Cards

\$100

\$200

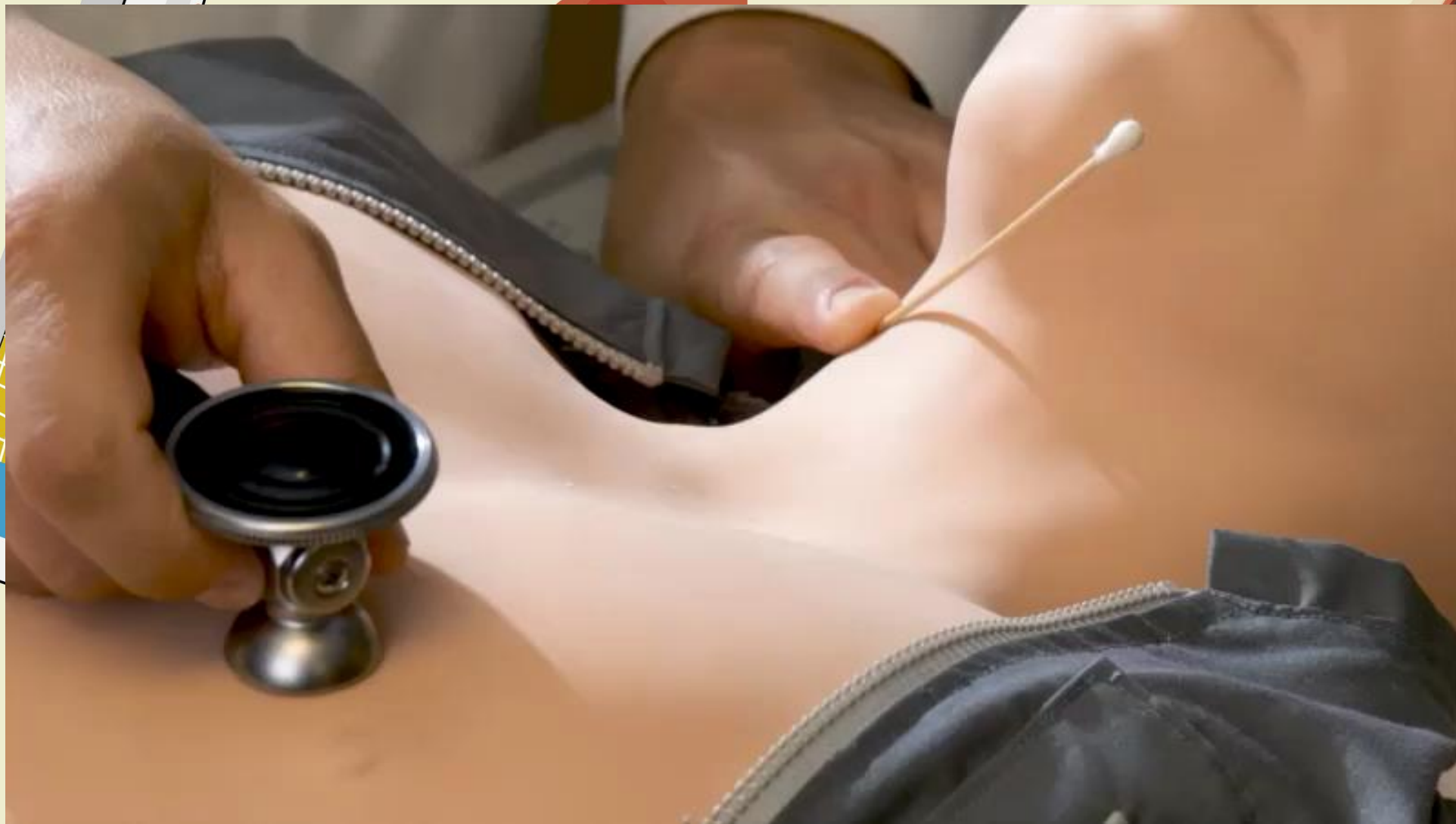\$300

\$400



**BAND-AID**  
BRAND ADHESIVE BANDAGE






*What best describes the acoustic events at the apex?*

Topic I

100

Question

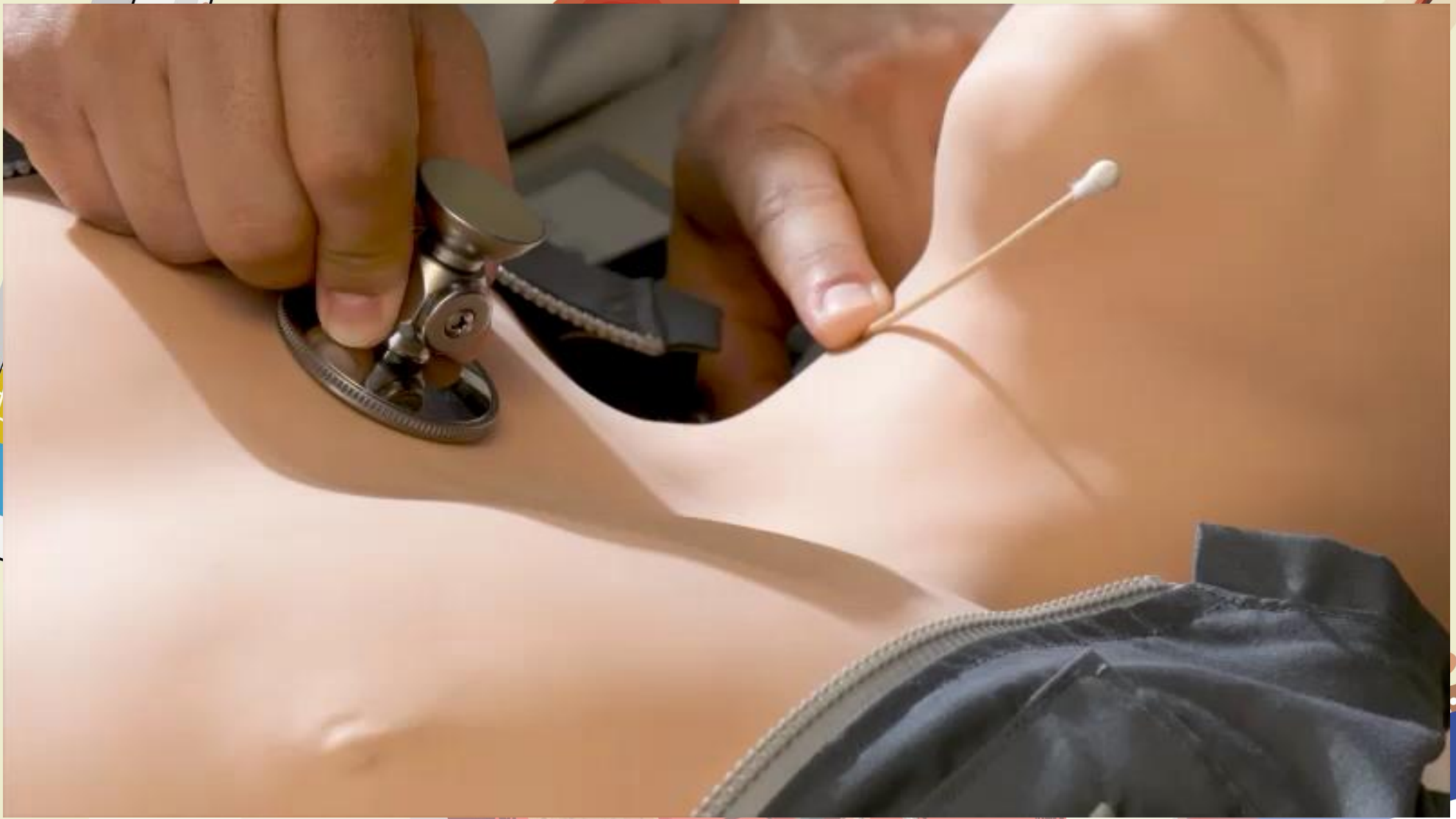

**BAND-AID**<sup>®</sup>  
BRAND ADHESIVE BANDAGES

## • MITRAL STENOSIS

- typical findings of mitral stenosis:
  - diastolic opening snap followed by a long, low-frequency diastolic murmur best heard at the apex
  - peaks during mid-diastole and again before a loud  $S_1$
- best heard with the bell of the stethoscope with pt in the left lateral decubitus position
- Often first diagnosed during pregnancy because of the increased intravascular volume and cardiac output






*What best describes the acoustic events at the apex?*

Topic I

200

Question



## • AORTIC STENOSIS

- Auscultation reveals a harsh crescendo-decrescendo systolic murmur at the upper right sternal edge compatible with aortic stenosis
- Murmur begins early in systole and extends nearly to  $S_2$
- The associated carotid pulsation, visually represented by the cotton swab on the carotid artery, may be small in volume and delayed (pulsation occurring slightly after  $S_1$ )






*What best describes the acoustic events at the apex?*

Topic I

300

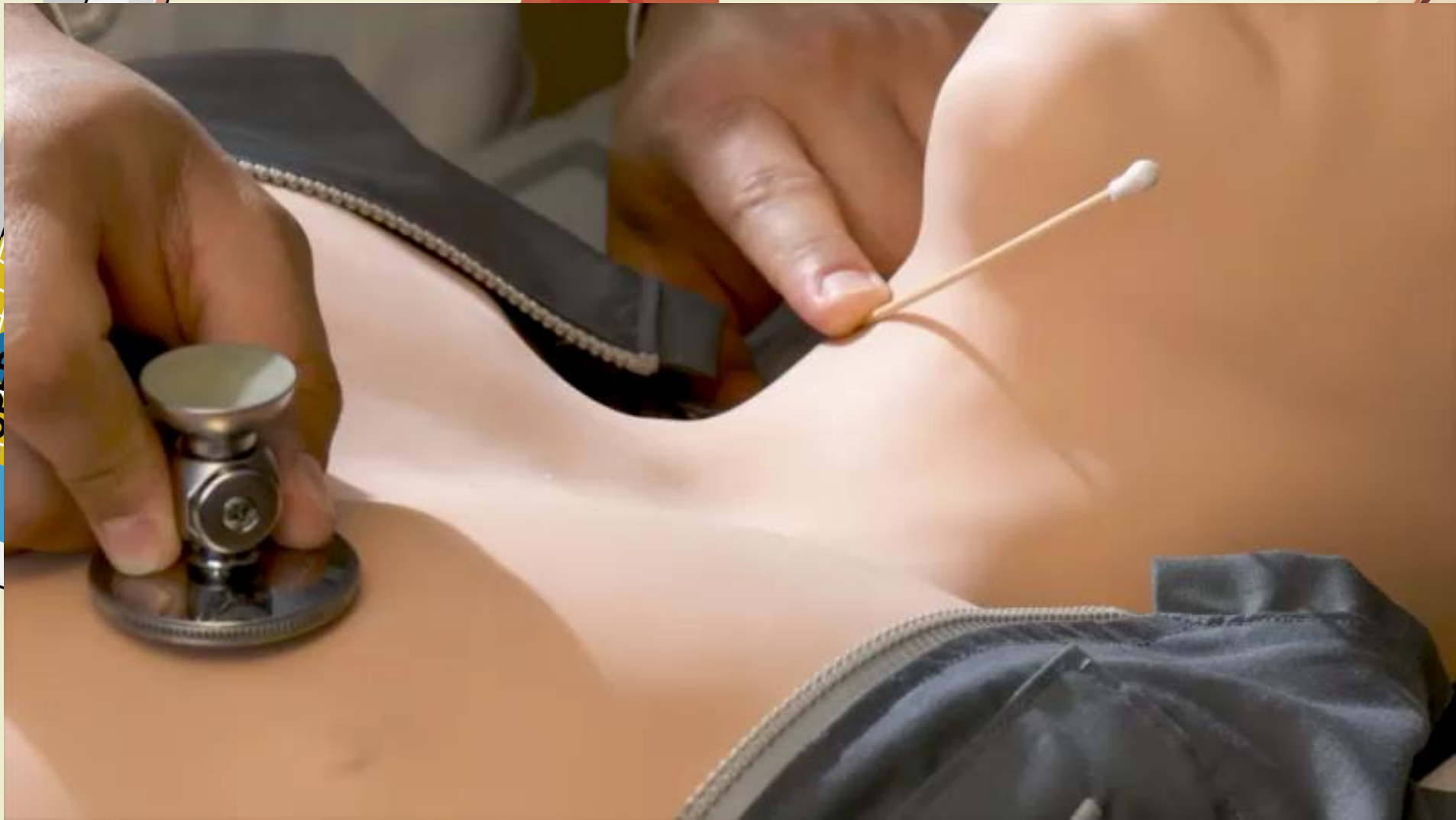Question



## • AORTIC REGURGITATION

- Characteristic high-pitched, long, blowing diastolic decrescendo murmur
- Murmur begins immediately after  $S_2$  and is best heard at the mid-left sternal edge
- In this ex.,  $S_2$  is nearly inaudible Best heard with the patient seated, leaning forward, and holding the breath at end-expiration
- The presence of a wide pulse pressure is also typical of chronic aortic regurgitation.






*What best describes the acoustic events at the apex?*

Topic I

400

Question

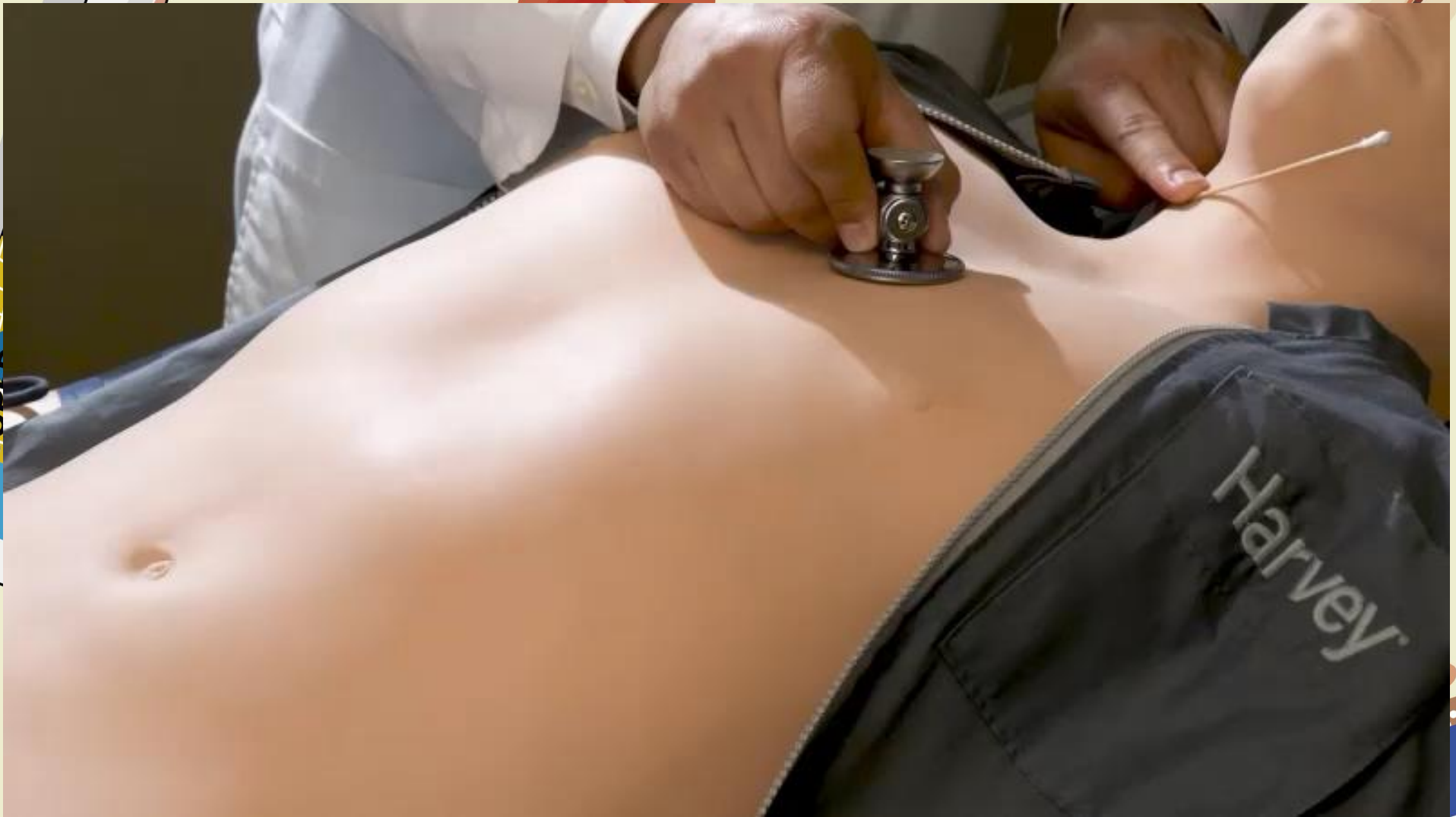

**BAND-AID**<sup>®</sup>  
BRAND ADHESIVE BANDAGES

## • MITRAL REGURGITATION

- Classically is a high-pitched, blowing holosystolic murmur, ending with  $S_2$ , loudest at the apex
- Radiates to the left axilla and left scapular area
- Not heard in this example, but associated  $S_3$  may indicate that the regurgitant flow volume is significant or that left heart failure with reduced ejection fraction has developed.






*What best describes the acoustic events at the apex?*

Topic II

100

Question



## • PERICARDIAL RUB

- The predominant sign of pericarditis
- Often described as creaking, grating, or scratching
- Heard best at the left sternal border with the patient sitting up, leaning forward, and holding the breath in expiration
- As in this example, pericardial rubs may vary in intensity with respiration.






*What best describes the acoustic events at the apex?*

Topic II

200

Question



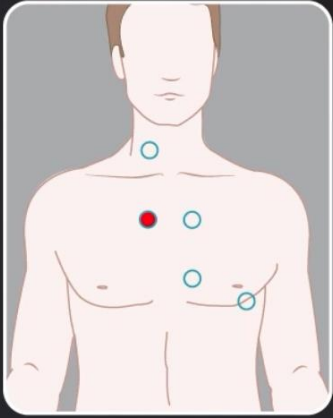
**BAND-AID**<sup>®</sup>  
BRAND ADHESIVE BANDAGES

## • PHYSIOLOGIC SPLIT S<sub>2</sub>

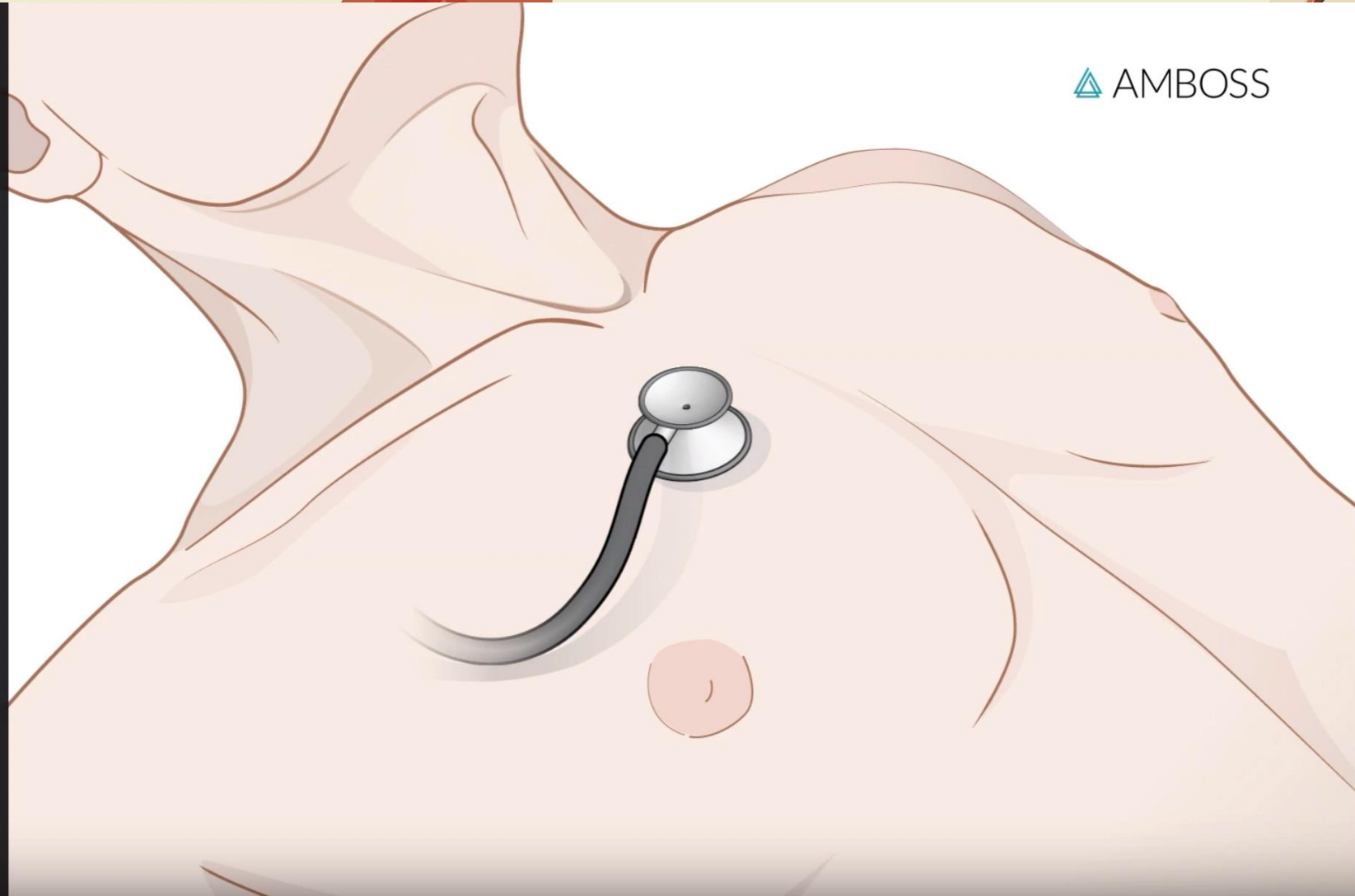
- In this patient, auscultation reveals normal splitting of S<sub>2</sub> during inspiration.
- Both components of a split S<sub>2</sub> are high-frequency sounds heard best with the diaphragm in the second left intercostal space.
- Splitting of S<sub>2</sub> represents asynchronous closure of the aortic and pulmonic valves
- In the normal adult, splitting varies with the respiratory cycle and is perceived as a single S<sub>2</sub> during expiration and a double S<sub>2</sub> during inspiration.



00:00



AMBOSS




*What best describes the acoustic events at the apex?*

Topic II

300

Question




**BAND-AID**<sup>®</sup>  
BRAND ADHESIVE BANDAGES

## • S<sub>3</sub>

- An S<sub>3</sub> is a low-frequency, early diastolic sound best heard with the bell of the stethoscope at the cardiac apex
- It may be perceived as a double S<sub>2</sub>
- Can position patient in the left lateral decubitus position
- Often heard in HFrEF but also in volume overload states, such as valvular regurgitation, shunt lesions, or late pregnancy
- An S<sub>3</sub> can also represent a normal finding in children or highly trained athletes.



# DAILY DOUBLE



**D-AID**<sup>®</sup>  
ESIVE BANDAGES



A 48 y/o F presents for a new-patient visit. She is asymptomatic and sedentary but recently joined a gym. She feels “out of shape” but can ride a stationary bike with moderate intensity for 30 min. Medical history is unremarkable and takes no medications.

On PE, vitals are WNL. Estimated CVP is 6 cm H<sub>2</sub>O. Apical impulse is not palpable. There is a grade 2/6 midsystolic murmur at the LSB without radiation. The murmur does not change with respiration or handgrip but diminishes in with standing. The S<sub>2</sub> is physiologically split. There are no clicks. Lungs are clear. Pulses are normal. No edema is present. What is the most appropriate management?






## Routine clinical follow-up without imaging

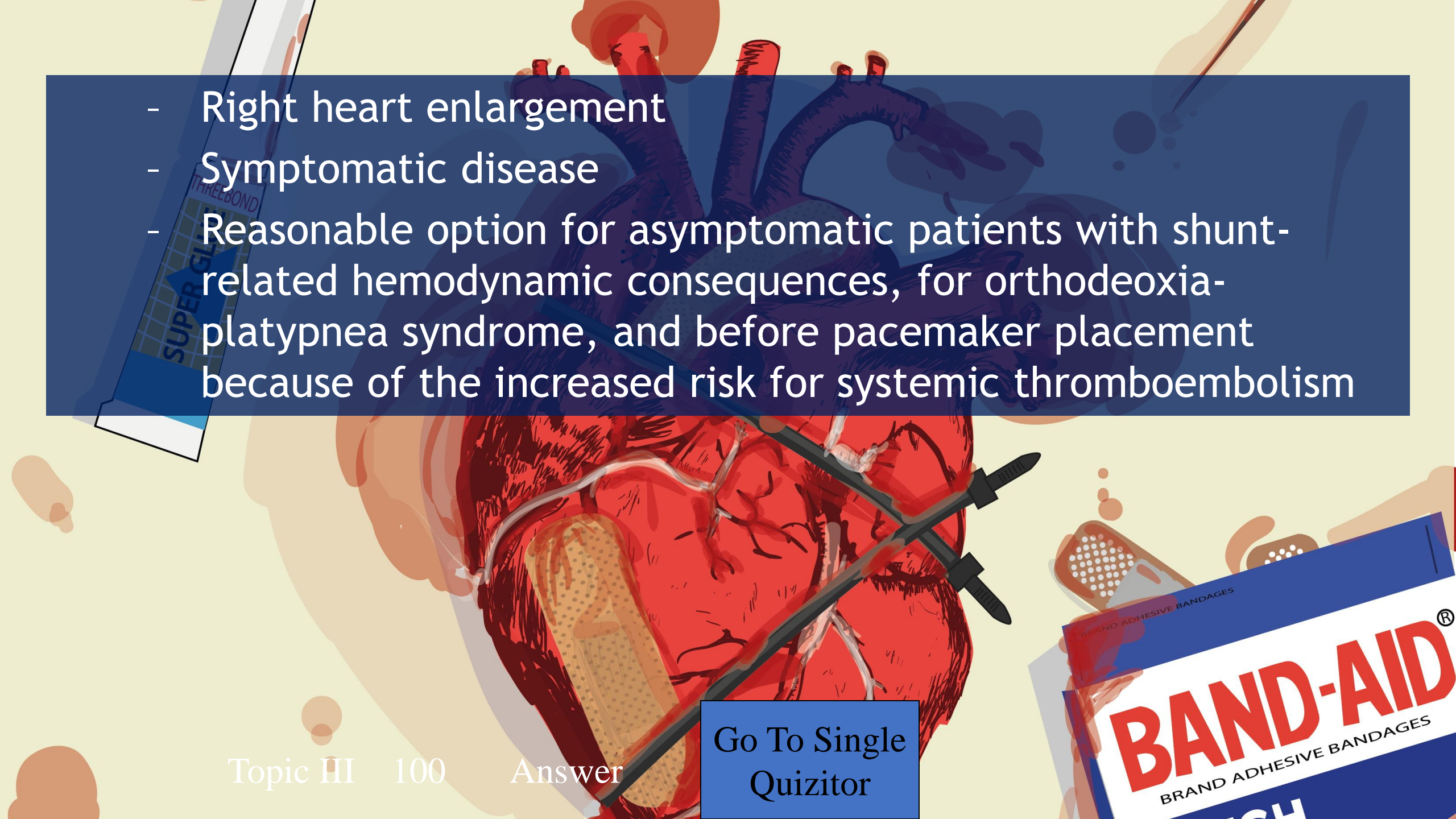
- Not all systolic murmurs are pathologic.
- Asymptomatic patients with short, soft systolic murmurs (grade <3) well localized to the left sternal border and associated with normal heart sounds do not usually require further investigation.
- Benign murmurs typically decrease in intensity with standing.
- The presence of any diastolic or continuous murmur, cardiac symptoms (chest pain, dyspnea, syncope), or abnormalities on examination (clicks, abnormal S<sub>2</sub>, abnormal pulses) requires evaluation by echocardiography.

An anatomical illustration of a human heart in red, with a surgical instrument (forceps) positioned over it. A blue semi-transparent rectangular box is overlaid on the heart, containing the text 'Name 2 Indications for ASD closure'. The background is a light beige color with various medical-related icons: a tube of 'THREBOND SUPER GLUE' on the left, a box of 'BAND-AID BRAND ADHESIVE BANDAGES' on the bottom right, and a blue play button icon at the bottom center.

Name 2 Indications for ASD closure






- 
- An anatomical illustration of a human heart in red, with a pacemaker lead inserted into the right ventricle. A yellow Band-Aid adhesive bandage is placed over the lead's exit point on the chest. The background is a light yellow with faint medical icons like a syringe and a stethoscope. A dark blue semi-transparent box contains a list of clinical points.
- Right heart enlargement
  - Symptomatic disease
  - Reasonable option for asymptomatic patients with shunt-related hemodynamic consequences, for orthodeoxia-platypnea syndrome, and before pacemaker placement because of the increased risk for systemic thromboembolism



An 18-year-old man is evaluated for a murmur detected during a college sports physical examination. He reports no symptoms and has no history of cardiac disease. He takes no medications.

On physical examination, vital signs are normal. He has a normal central venous pressure, waveform, precordial palpation, and  $S_1$ . A continuous murmur is heard beneath the left clavicle that envelops the  $S_2$ . The remainder of the examination is unremarkable.

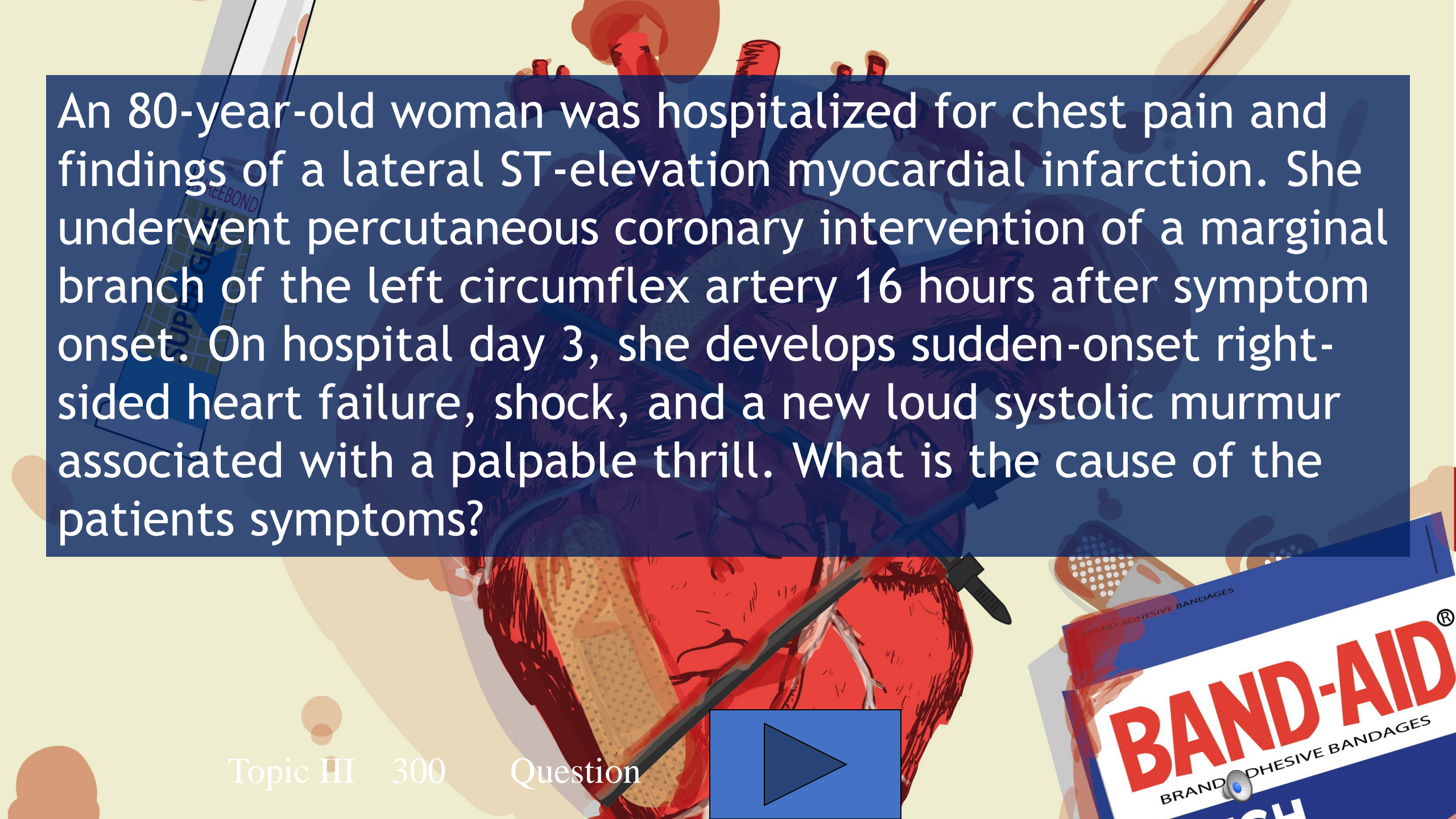
What is the most likely cause of the murmur?






## Patent ductus arteriosus (PDA)

- A continuous murmur heard beneath the left clavicle that envelops the  $S_2$  is typical of a PDA; it is often described as a “machinery” murmur
- A tiny PDA is generally asymptomatic with an inaudible murmur.
- Patients with a small PDA may have an audible murmur but no other cardiovascular features
- Patients with a moderate-sized PDA may have bounding pulses, a wide pulse pressure, left heart enlargement and dysfunction, and clinical heart failure.
- A large PDA may present with pulmonary hypertension and shunt reversal (Eisenmenger syndrome) in adults.

An anatomical illustration of a human heart in red and orange tones. A Band-Aid is applied to the left ventricle. A syringe is positioned near the heart. The background is a light yellow with faint medical icons like a stethoscope and a pill. A dark blue semi-transparent box contains white text.

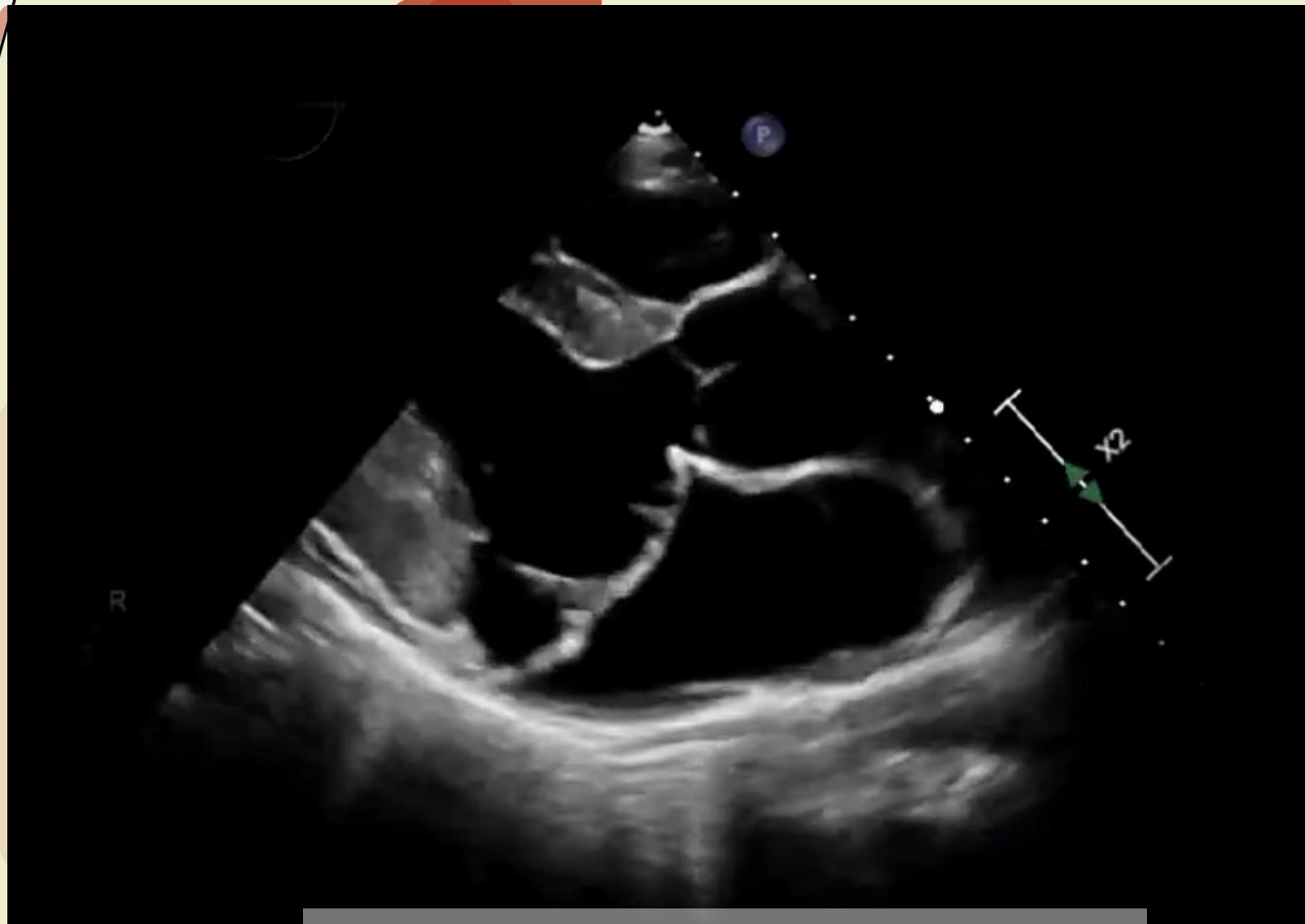
An 80-year-old woman was hospitalized for chest pain and findings of a lateral ST-elevation myocardial infarction. She underwent percutaneous coronary intervention of a marginal branch of the left circumflex artery 16 hours after symptom onset. On hospital day 3, she develops sudden-onset right-sided heart failure, shock, and a new loud systolic murmur associated with a palpable thrill. What is the cause of the patients symptoms?





## ACQUIRED VENTRICULAR SEPTAL DEFECT

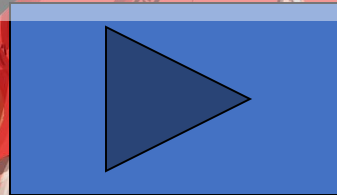
- With MI seen typically with anterior or inferior MI
  - Associated with transmural infarction
- With only medical management mortality is ~100%
- Typically occur within 3 to 5 days of STEMI presentation
- Presents with worsening CHF and shock, and a harsh holosystolic murmur may be heard at the LLSB



*What pathology is seen here?*

Topic III 400

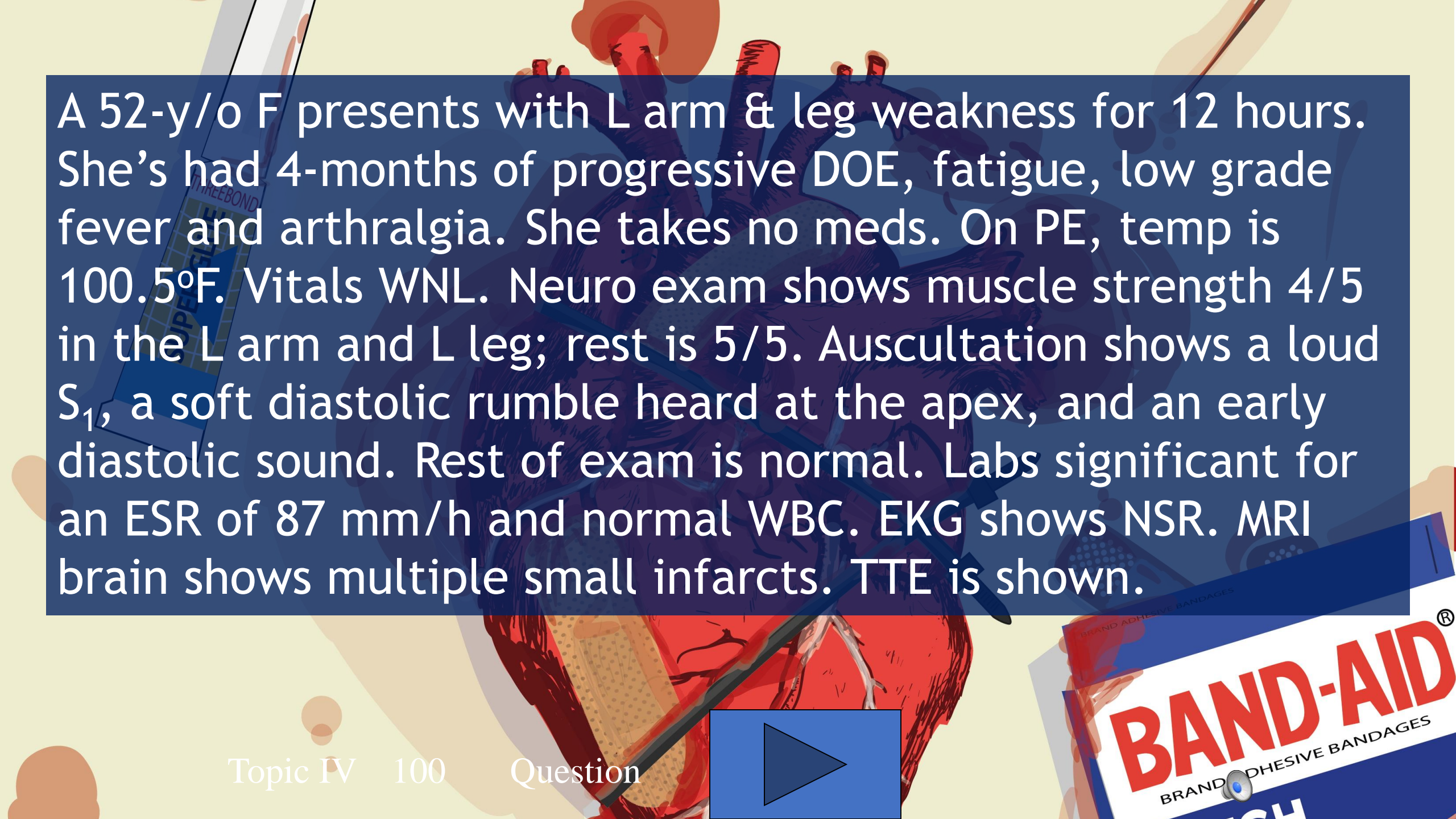
Question






## MITRAL VALVE PROLAPSE

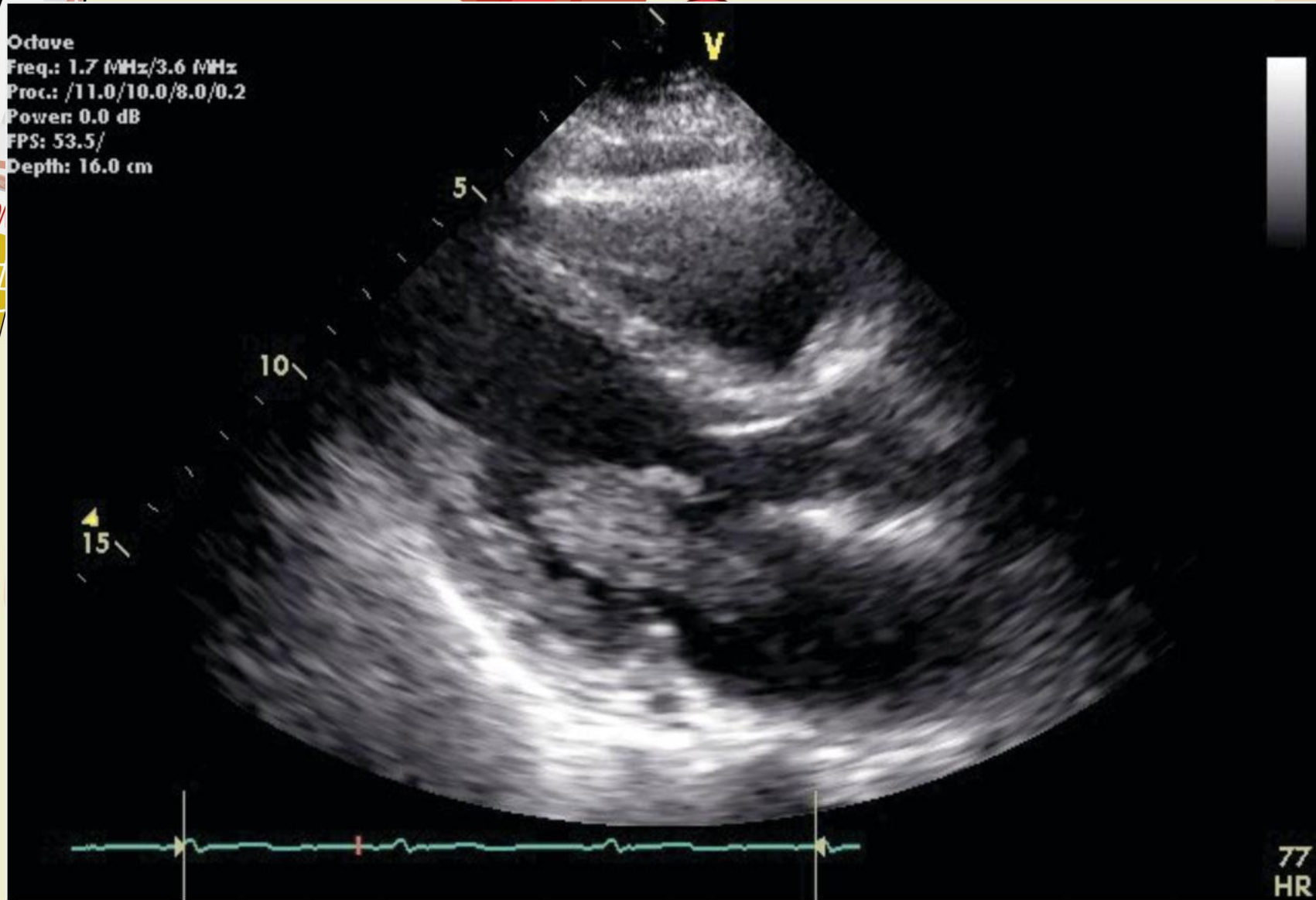
- Present in 1-2% of population
- Usually a benign prognosis
- May have one or more systolic clicks preceding the murmur, and variation in severity, preload, and afterload can lead to differences in murmur onset (holosystolic, midsystolic, or late systolic).
- If has associated LV dilatation, the apical impulse may be displaced laterally, and an  $S_3$  may be audible
- If there is a flail then annual mortality rate increased than compared to if just regurgitation



A 52-y/o F presents with L arm & leg weakness for 12 hours. She's had 4-months of progressive DOE, fatigue, low grade fever and arthralgia. She takes no meds. On PE, temp is 100.5°F. Vitals WNL. Neuro exam shows muscle strength 4/5 in the L arm and L leg; rest is 5/5. Auscultation shows a loud  $S_1$ , a soft diastolic rumble heard at the apex, and an early diastolic sound. Rest of exam is normal. Labs significant for an ESR of 87 mm/h and normal WBC. EKG shows NSR. MRI brain shows multiple small infarcts. TTE is shown.







*What is the most appropriate treatment?*

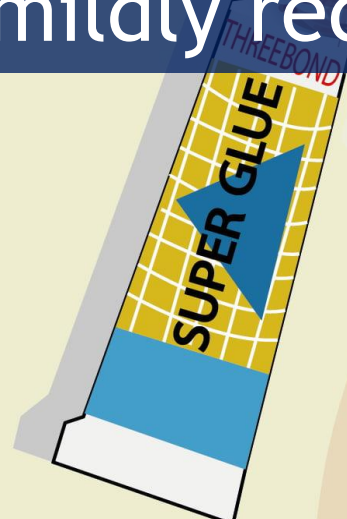
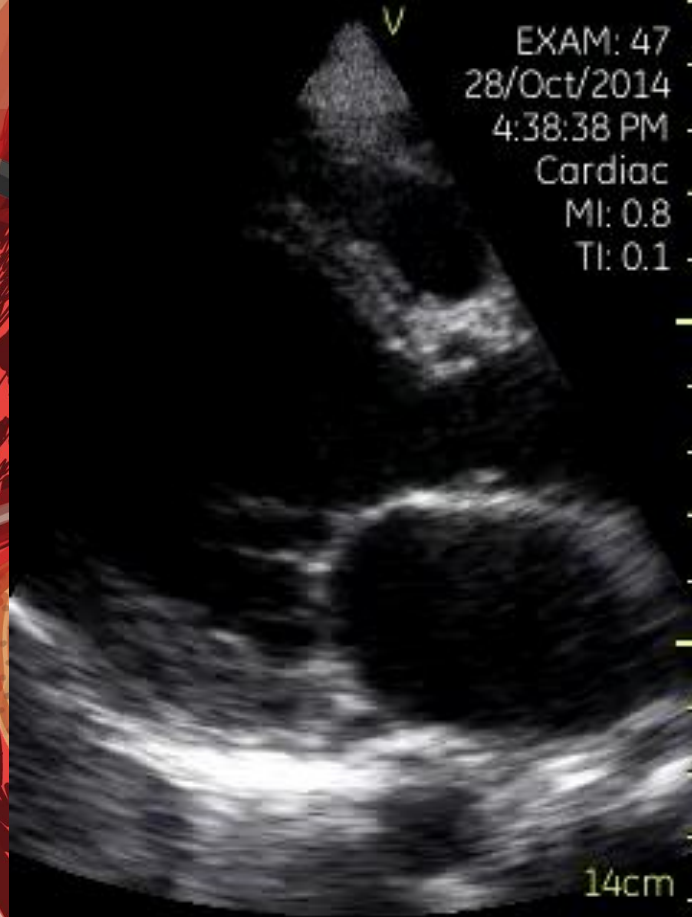


# SURGICAL EXCISION

- This patient's history, PE and echo findings are all most consistent with a left atrial myxoma
- Myxomas are connective tissue tumors, mostly attached to the left atrial wall in proximity to the fossa ovalis.
- Patients most often present with symptoms related to obstruction or embolization, or constitutional symptoms such as fatigue, low-grade fever, and arthralgia.
- Dyspnea related to mitral valvular obstruction, which causes a diastolic rumble resembling mitral stenosis and an early diastolic sound (“tumor plop”) heard in 10% to 15% of patients
- Treatment for an atrial myxoma is urgent surgical excision.



A 64-year-old woman is evaluated for dyspnea. Focused point-of-care cardiac ultrasonography is performed. Is this mildly reduced, severely reduced or normal?

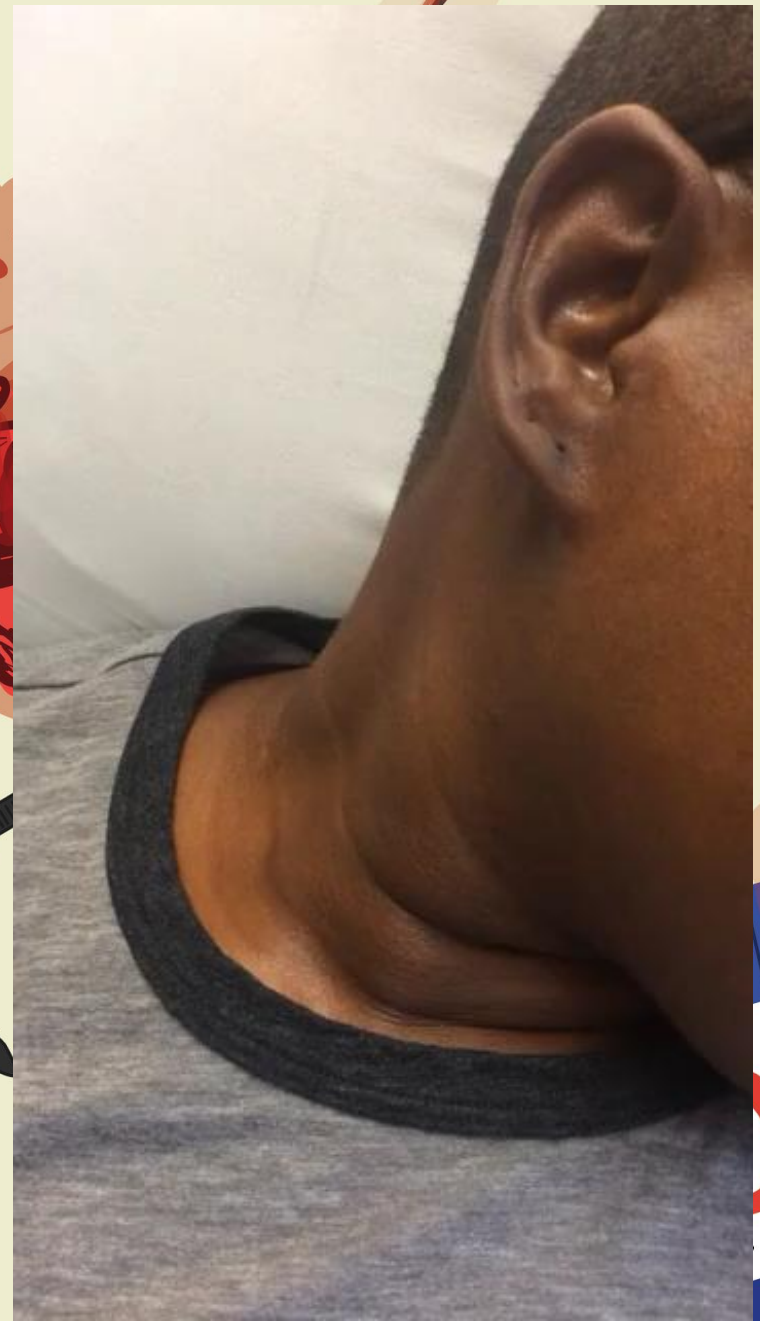


## SEVERELY REDUCED

- This patient's left ventricular function is severely reduced
- The ultrasound shows a long-axis view of the left ventricle
- The chamber of the LV is abnormally large and round, and its size decreases minimally during systole
- Additionally, the anterior leaflet of the mitral valve is quite far from the interventricular septum when opening during diastole



A 43-year-old man is evaluated for hypotension. Which of the following is the cause: sepsis, blood loss, heart failure, allergic reaction?






# HEART FAILURE

- This neck exam reveals jugular venous distension, reflecting increased right atrial pressure, which is most likely caused by left-sided heart failure.



A 63 y/o M is evaluated in the ED for progressive dyspnea. He reports orthopnea. He has a history of A.fib and underwent catheter ablation 1 week ago. Only other history is hypertension. He has no history of heart failure or LV dysfunction. Meds are warfarin, dronedarone, and lisinopril. On PE, temp is normal, BP is 88/72 mm Hg, HR is 112/min, and RR 16/min. Pulsus paradoxus of 12 mm Hg is present. O2 sats are 96% on RA. Cardiac examination reveals elevated estimated CVP. Heart sounds are difficult to auscultate. Lung examination reveals no crackles. EKG shows sinus tachycardia. What is the diagnosis responsible for the pt's condition?



# CARDIAC TAMPONADE

- Should be suspected when the patient has a compatible history, hypotension, elevated jugular venous pressure, narrow pulse pressure, and pulsus paradoxus
- An enlarged cardiac silhouette may be seen on CXR (“water-bottle heart”)
- The electrocardiogram typically demonstrates sinus tachycardia and electrical alternans
- Echo readily detects pericardial effusions and is the primary modality for diagnosing cardiac tamponade



# FINAL JEOPARDY!

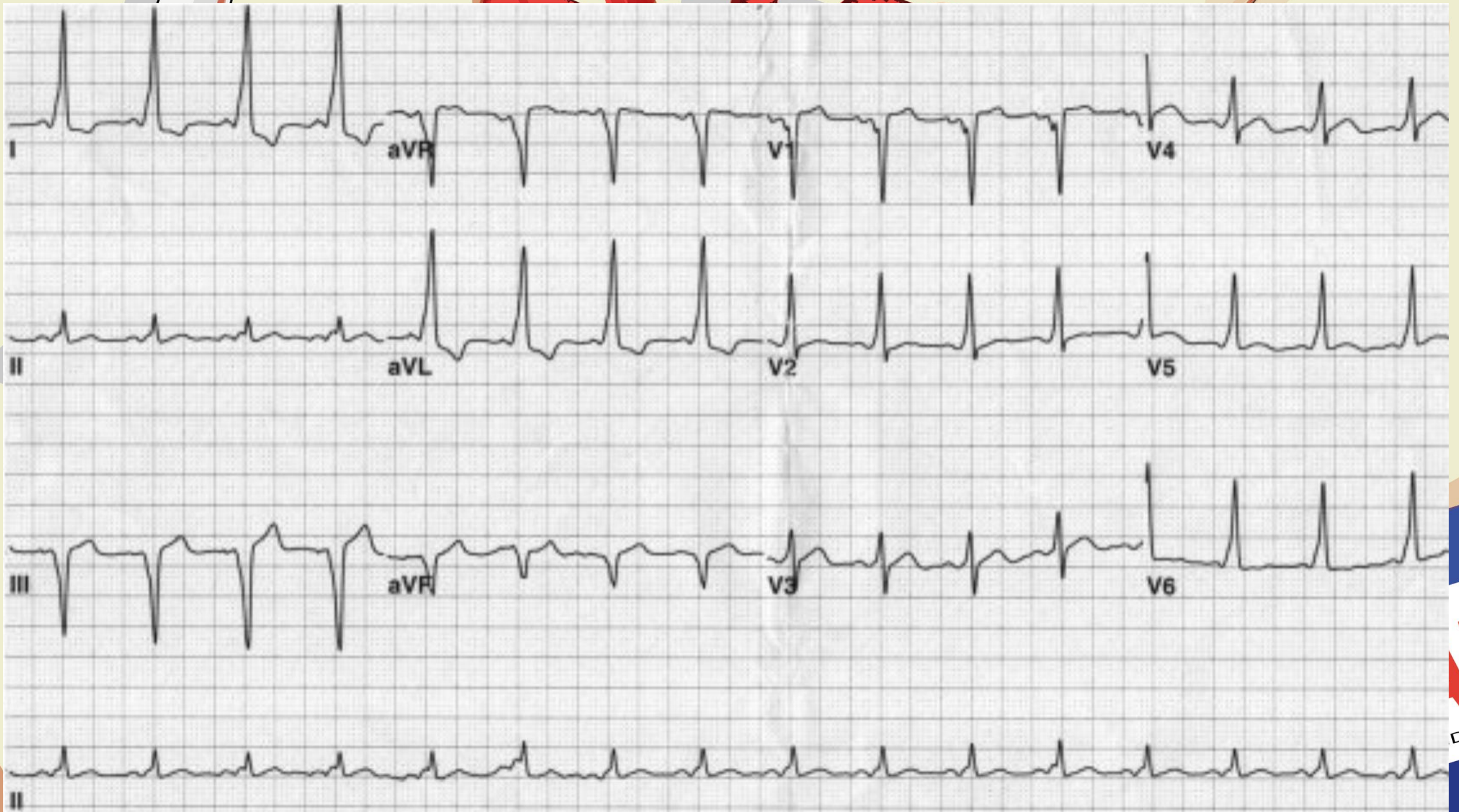**AID**<sup>®</sup>  
BANDAGES



# Dancing Without Rhythm



# What condition is responsible for the changes on this EKG?



An anatomical illustration of a human heart in shades of red and orange. The heart is shown with its major vessels and is partially covered with two yellow adhesive bandages. A blue surgical instrument, possibly a scalpel or forceps, is positioned diagonally across the heart. In the top-left corner, there is a tube of 'THREBOND SUPER GLUE'. In the bottom-right corner, there is a box of 'BAND-AID BRAND ADHESIVE BANDAGES'. The background is a light beige color with some faint, abstract shapes.

# Wolff-Parkinson-White pattern